

WORKSHEETS (LEMBAR KERJA)

Mata Kuliah

: Anatomi

Materi

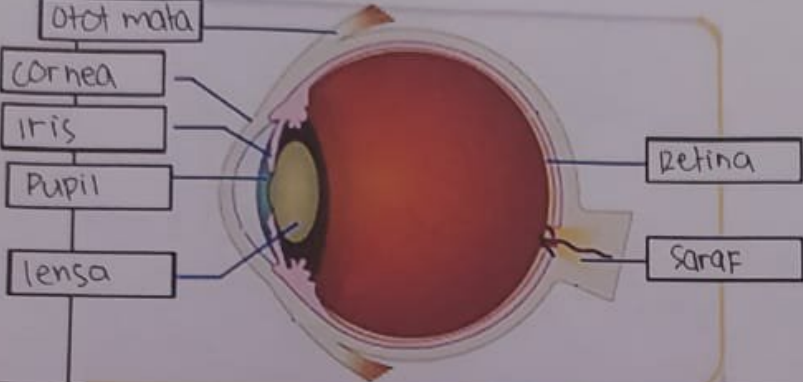
: Anatomi Panca Indra

NIM>Nama Mahasiswa

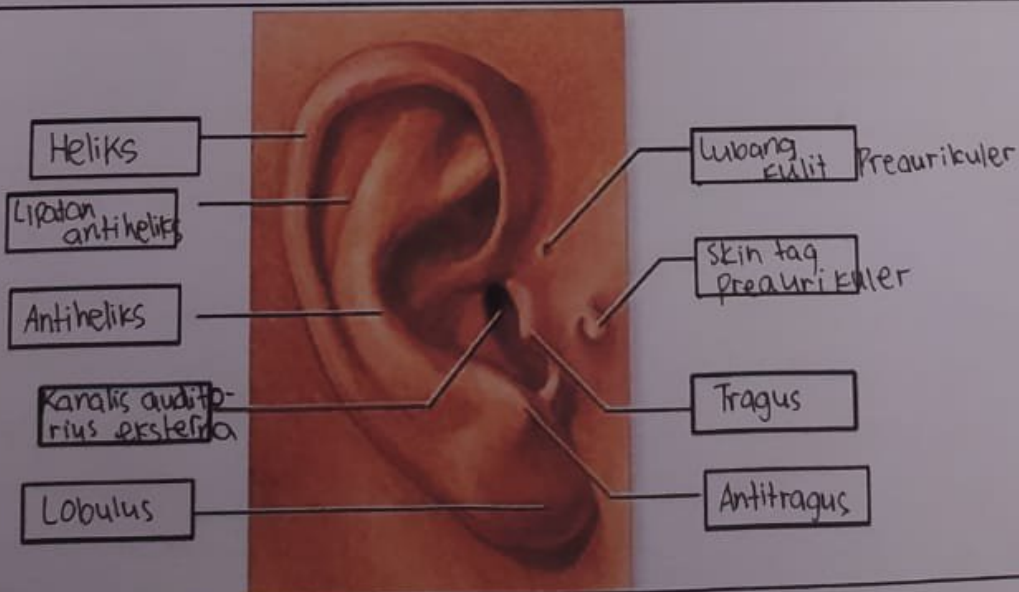
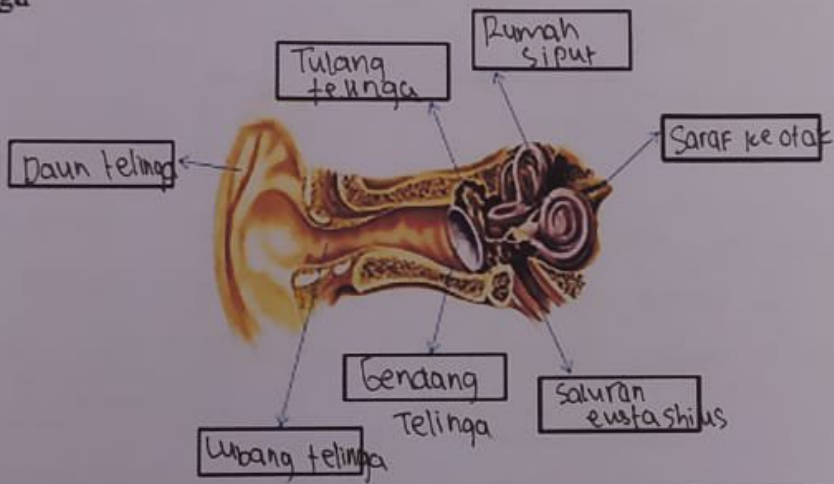
: Khusnul Hotimah NIM: 2110101119

No	Keterangan	Pembahasan
----	------------	------------

1 Mata



Telinga



No

Keterangan

Pembahasan

Posterior
semicircular
canal.

Lateral
semicircular
Canal

vestibuli

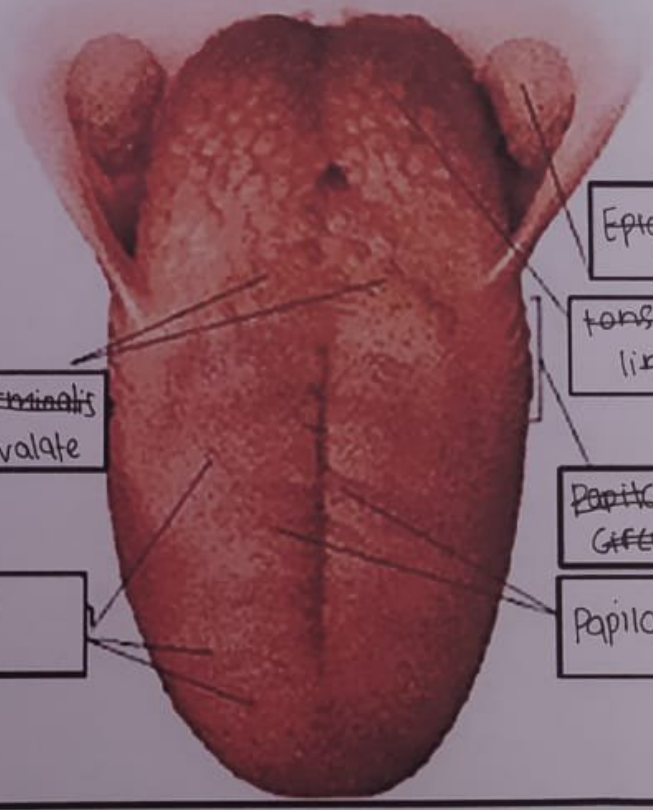


superior
Semicircular
canal

Nervus
vestibularis

Nervus
cochlearis

cochlea



~~Sulcus terminalis~~
Circum valate
Papillae

Fungi form
Papillae

Epiptolotis palatine
tonsil

tonsila
lingualis
Lingual
Tonsil

~~Papilla~~ Foliate
~~Circum valate~~ Papillae

Papilla Fungiformis