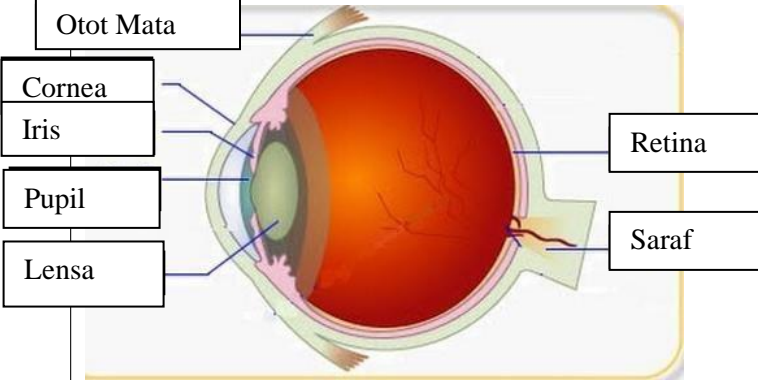
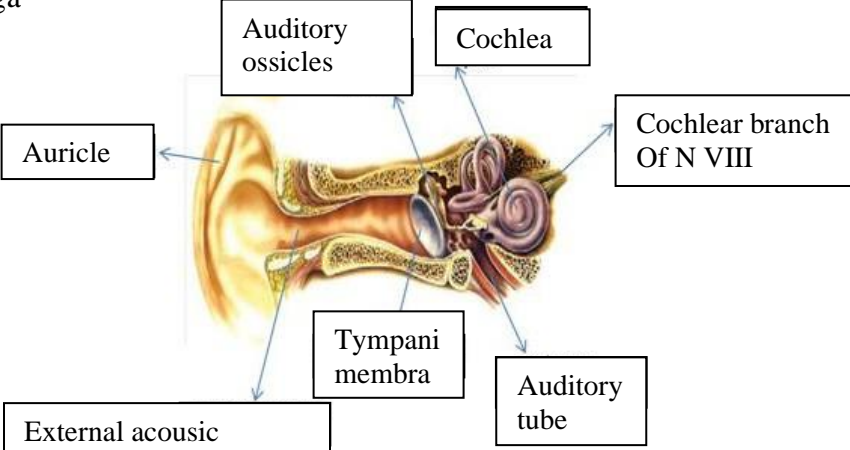

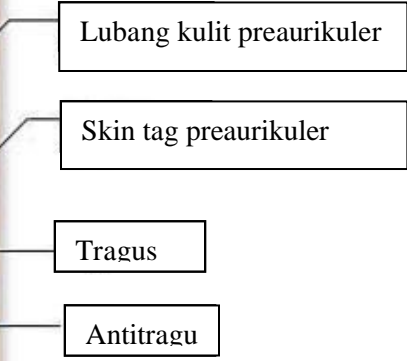
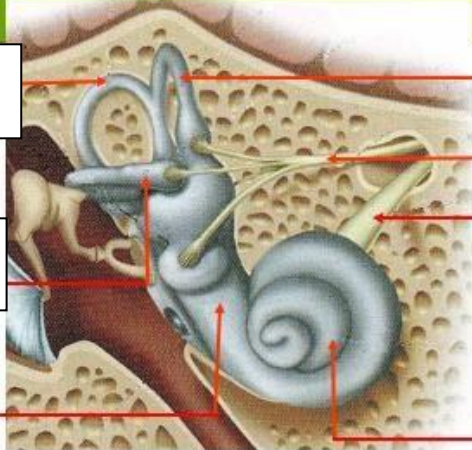
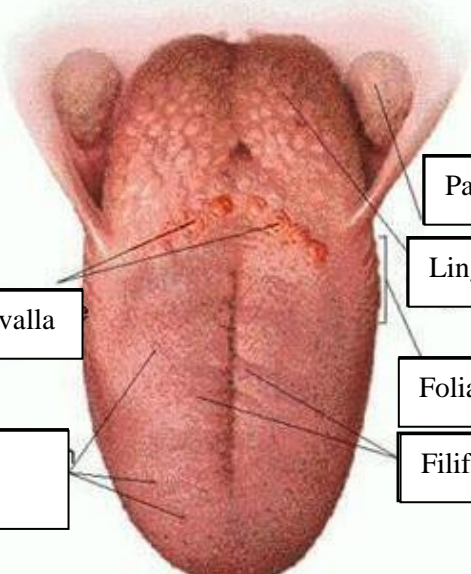


**WORKSHEETS (LEMBAR KERJA)**

<b>Mata Kuliah</b>	: <b>Anatomi</b>
<b>Materi</b>	: <b>Anatomi Panca Indra</b>
<b>NIM&gt;Nama Mahasiswa</b>	: <b>2110101079/ Afri Budi Setyaeni</b>

No	Keterangan	Pembahasan
1	<p>Mata</p> 	
	<p>Telinga</p> 	
		

No	Keterangan	Pembahasan
	 <p data-bbox="304 322 491 405">Semicircular Canals</p> <p data-bbox="304 495 491 577">Vestibular complex</p> <p data-bbox="225 667 448 719">Tingkap bundar</p>	<p data-bbox="991 322 1414 405">Semicircular canals within anterior semicircular canal</p> <p data-bbox="991 427 1267 551">1. Malleus 2. Incus 3. Stapes</p> <p data-bbox="991 562 1230 629">Saraf korea</p> <p data-bbox="991 663 1305 719">Konkrec (rumah siput)</p>
		 <p data-bbox="475 1025 671 1093">Circumvallata</p> <p data-bbox="432 1167 660 1256">Fungiform papillae</p> <p data-bbox="991 898 1230 954">Palatine tonsil</p> <p data-bbox="991 976 1209 1043">Lingual tonsil</p> <p data-bbox="991 1088 1230 1155">Foliate papillae</p> <p data-bbox="991 1167 1251 1234">Filiform papillae</p>