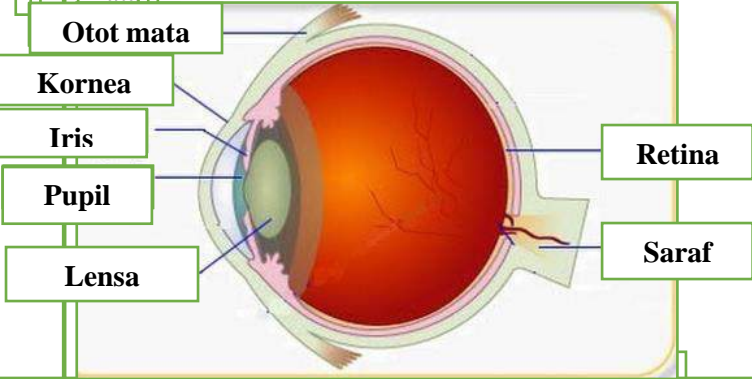
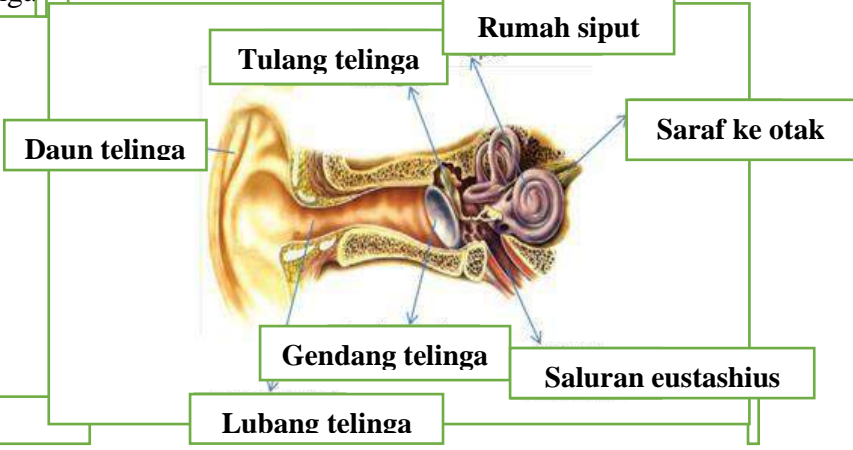
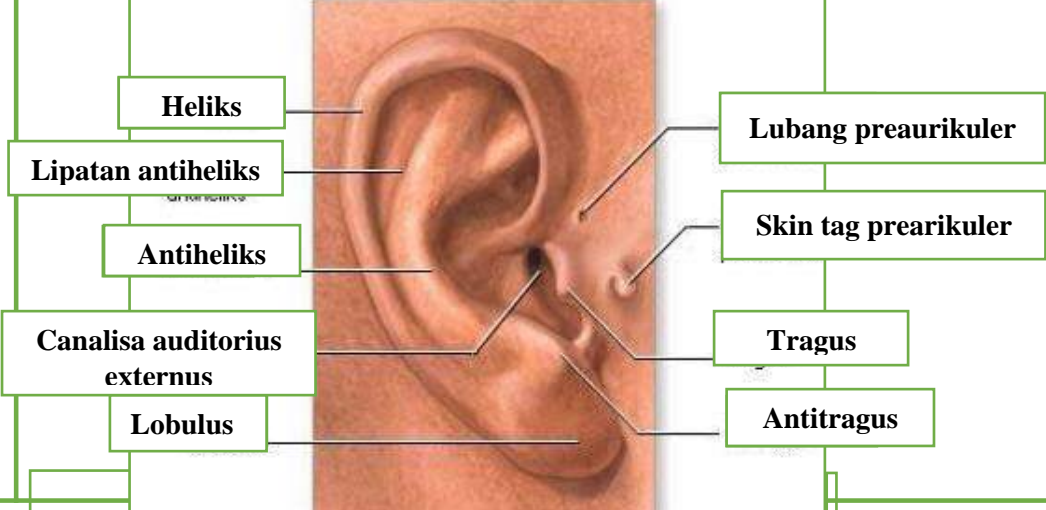
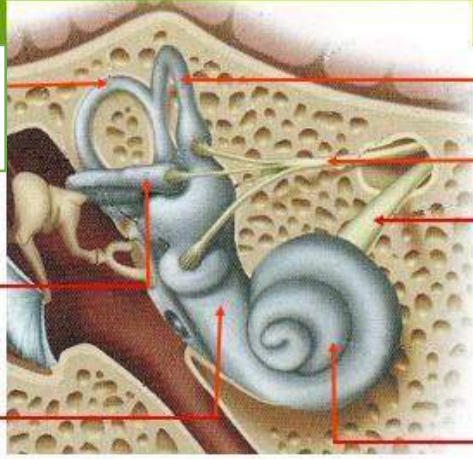
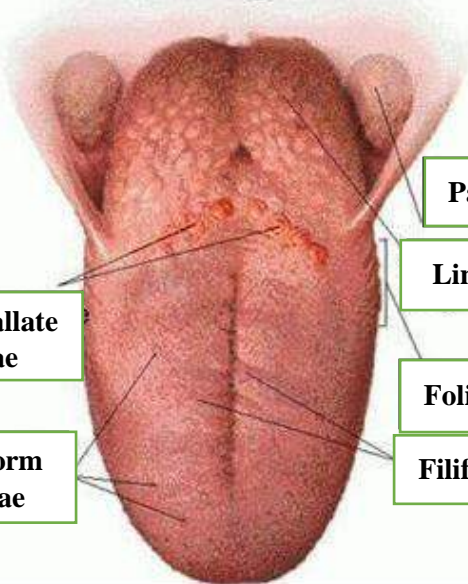


WORKSHEETS (LEMBAR KERJA)

Mata Kuliah	: Anatomi
Materi	: Anatomi Panca Indra
NIM>Nama Mahasiswa	: 2110101122/Novia Indri Lestari

No	Keterangan	Pembahasan
1	Mata	 <p>Diagram of the human eye showing internal structures. Labels include: Otot mata (eye muscle), Kornea (cornea), Iris, Pupil, Lensa (lens), Retina, and Saraf (nerve).</p>
	Telinga	 <p>Diagram of the human ear showing internal structures. Labels include: Daun telinga (pinna), Tulang telinga (ear bones), Rumah siput (cochlea), Saraf ke otak (nerve to brain), Gendang telinga (eardrum), Saluran eustashius (Eustachian tube), and Lubang telinga (ear canal).</p>
		 <p>Diagram of the external ear showing external structures. Labels include: Heliks (helix), Lipatan antiheliks (antihelical fold), Antiheliks (antihelix), Canalis auditorius externus (external auditory canal), Lobulus (lobule), Lubang preaurikuler (preauricular pit), Skin tag preaurikuler (preauricular skin tag), Tragus, and Antitragus.</p>

No	Keterangan	Pembahasan
	<p>Posterior Semicircular canal</p> <p>Lateral Semicircular canal</p> <p>Vestibuli</p>	 <p>Superior semicircular canal</p> <p>Nervus vestibularis</p> <p>Nervus cochlearis</p> <p>Cochlea</p>
	<p>Circumvallate papillae</p> <p>Fungiform papillae</p>	 <p>Palatine tonsil</p> <p>Lingual tonsil</p> <p>Foliate papillae</p> <p>Filiform papillae</p>