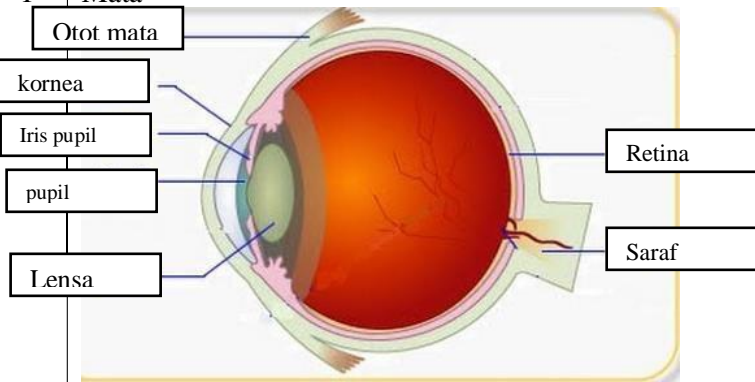
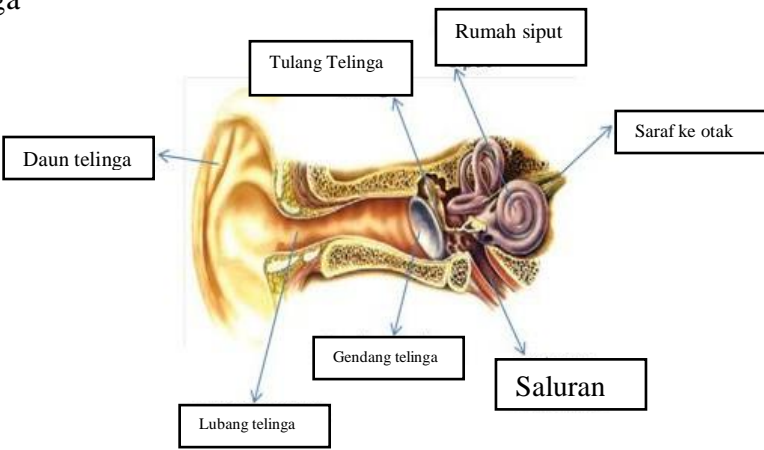
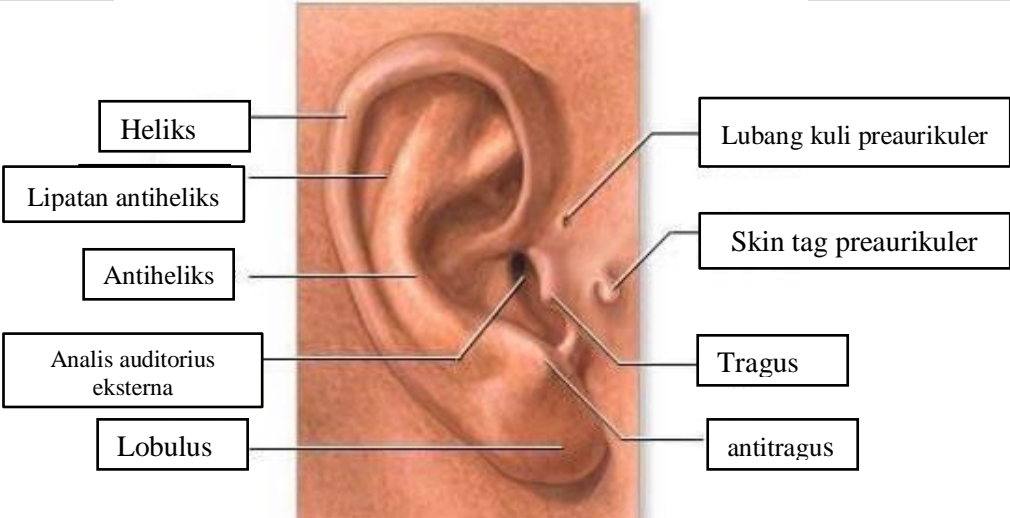
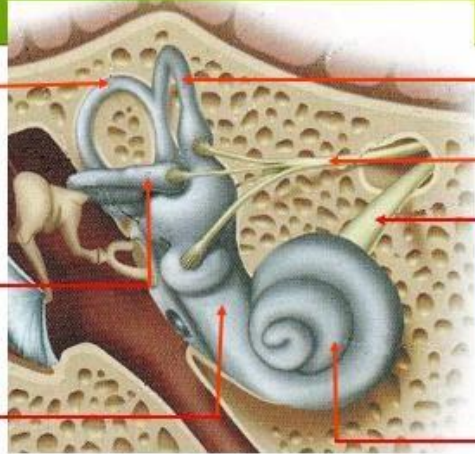
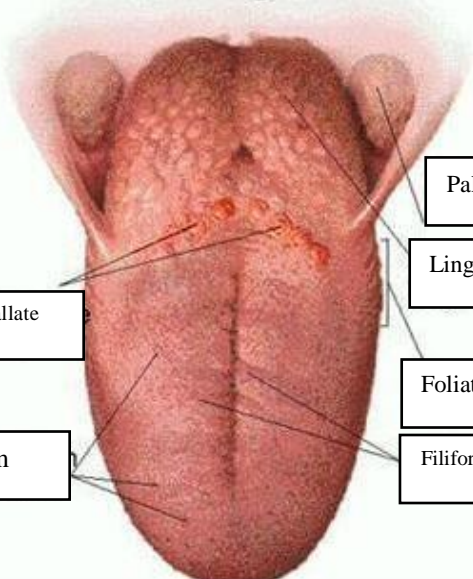


**WORKSHEETS (LEMBAR KERJA)**

<b>Mata Kuliah</b>	: <b>Anatomi</b>
<b>Materi</b>	: <b>Anatomi Panca Indra</b>
<b>NIM&gt;Nama Mahasiswa</b>	: <b>2110101080/Khotim Nur Khasanah</b>

No	Keterangan	Pembahasan
1	<p><b>Mata</b></p> 	
	<p><b>Telinga</b></p> 	
		

No	Keterangan	Pembahasan
	<p>Posterior Semicircular canal</p> <p>Lateral semicircular canal</p> <p>vestibuli</p>	 <p>Superior semicircular canal</p> <p>Nervus Vestibularis</p> <p>Nervus Cochlearis</p> <p>cochlea</p>
	<p>Circumvallate papillae</p> <p>Fungiform</p>	 <p>Palatine Tonsil</p> <p>Lingual Tonsil</p> <p>Foliate papillae</p> <p>Filiform papillae</p>