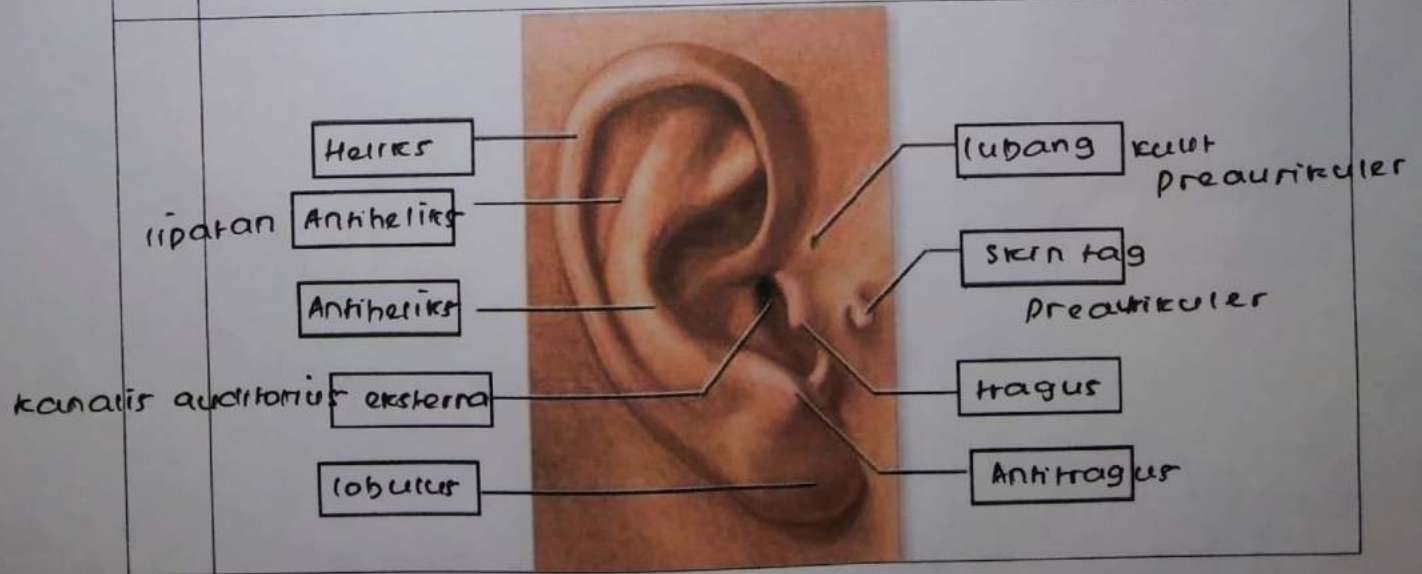
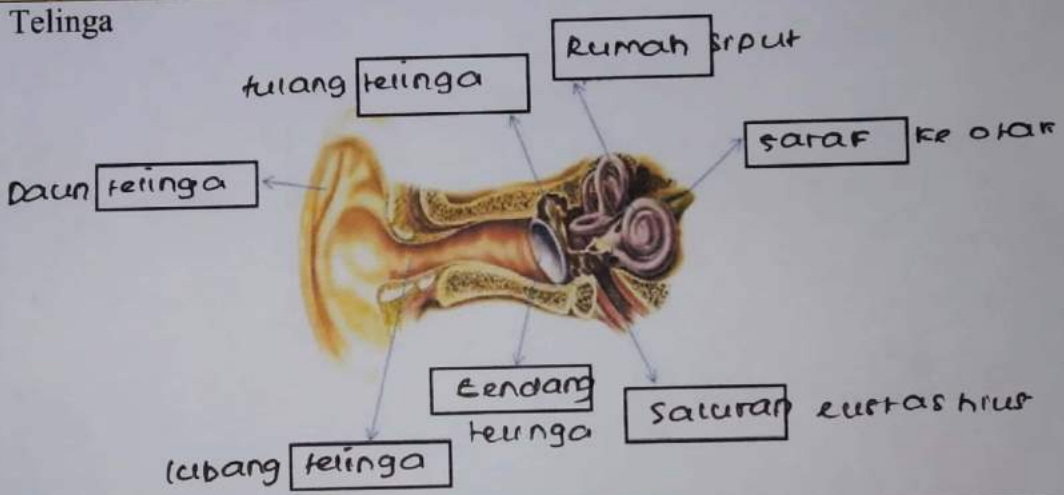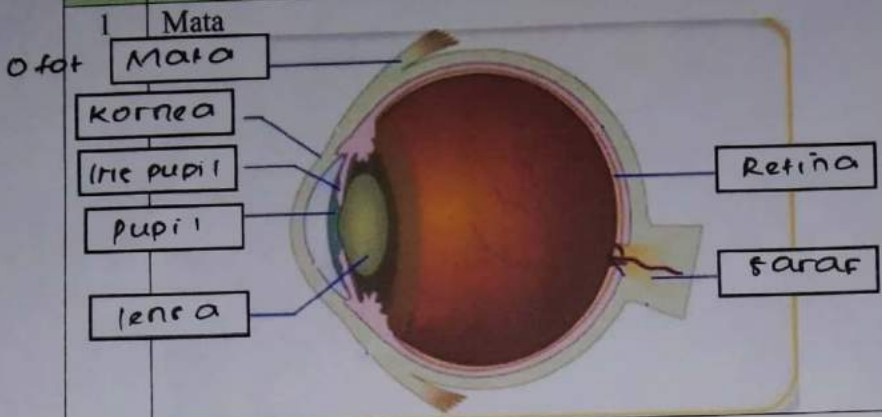



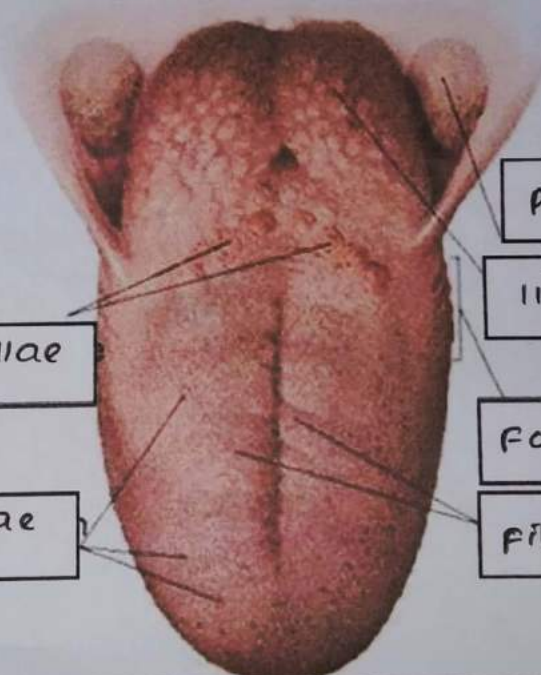
WORKSHEETS (LEMBAR KERJA)

| | |
|--------------------|--|
| Mata Kuliah | : Anatomi |
| Materi | : Anatomi Panca Indra |
| NIM>Nama Mahasiswa | : 2110101069 / putri wafa norashila Dewi |

| No | Keterangan | Pembahasan |
|----|------------|------------|
|----|------------|------------|



| No | Keterangan | Pembahasan |
|----|--|---|
| | <p>posterior semicircular canal</p> <p>lateral semicircular canal</p> <p>vestibuli</p> |  <p>superior semicircular canal</p> <p>vestibular nerve</p> <p>saraf pendengaran</p> <p>Rumah siput / koklea</p> |

| | | |
|--|---|---|
| | <p>circumvallate papillae</p> <p>fungiform papillae</p> |  <p>palatine tonsil</p> <p>lingual tonsil</p> <p>foliate papillae</p> <p>filiform papillae</p> |
|--|---|---|