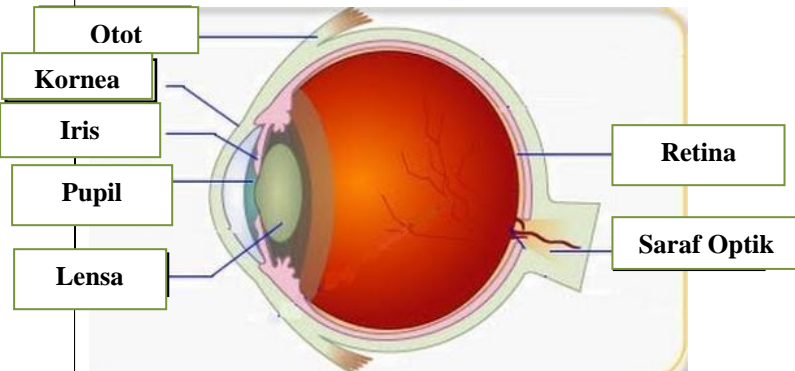
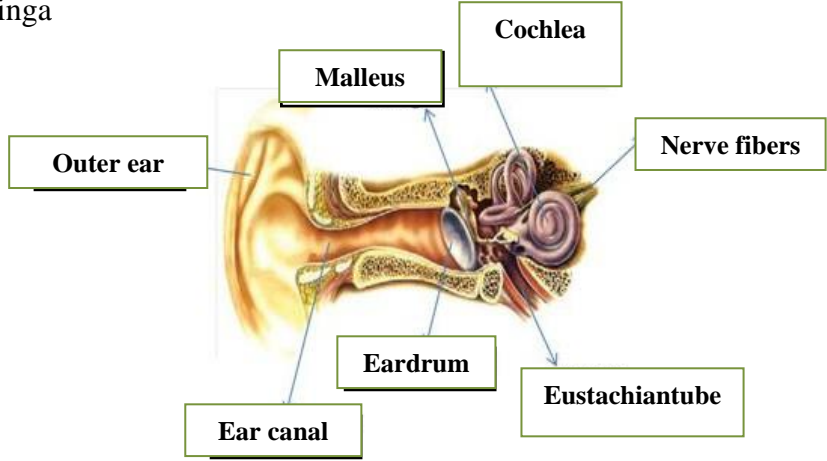
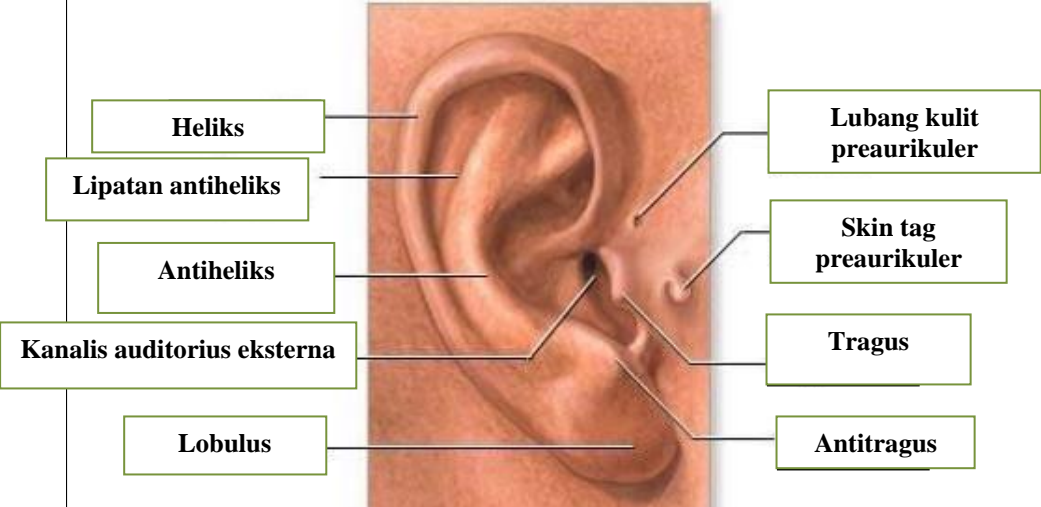
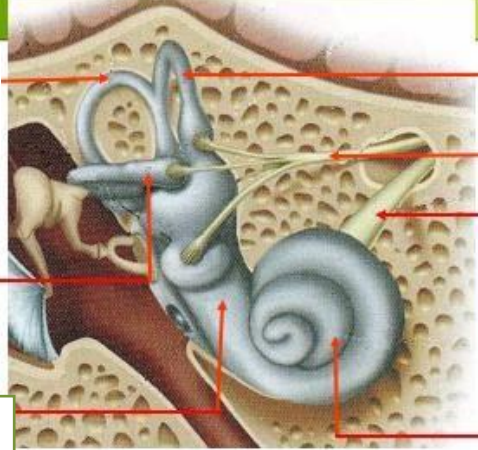
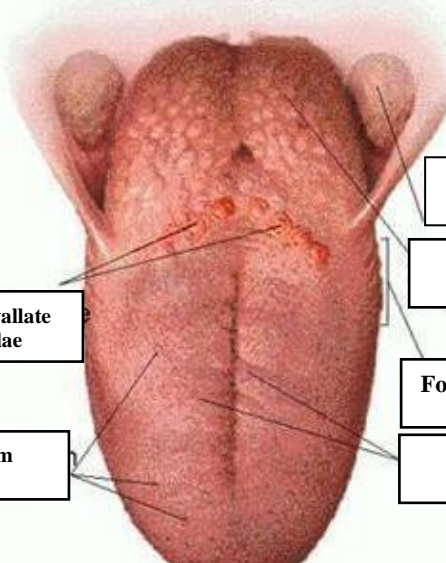


**WORKSHEETS (LEMBAR KERJA)**

<b>Mata Kuliah</b>	: Anatomi
<b>Materi</b>	: Anatomi Panca Indra
<b>NIM&gt;Nama Mahasiswa</b>	: 2110101115 / SHOFIYATUL AZIZAH

No	Keterangan	Pembahasan
		 <p>Diagram of the human eye showing internal structures. Labels include: Otot (Muscle), Kornea (Cornea), Iris, Pupil, Lensa (Lens), Retina, and Saraf Optik (Optic Nerve).</p>
	<p>Telinga</p>	 <p>Diagram of the human ear showing internal and external structures. Labels include: Outer ear, Ear canal, Eardrum, Malleus, Cochlea, Eustachiantube, and Nerve fibers.</p>
		 <p>Close-up diagram of the external ear. Labels include: Heliks (Helix), Lipatan antiheliks (Antihelical fold), Antiheliks (Antihelix), Kanalis auditorius eksterna (External auditory canal), Lobulus (Lobule), Lubang kulit preaurikuler (Preauricular skin pit), Skin tag preaurikuler (Preauricular skin tag), Tragus, and Antitragus.</p>

No	Keterangan	Pembahasan
	<p>Posterior semicircular canal</p> <p>Lateral semicircular canal</p> <p>Vestibularis</p>	 <p>Superior semicircular canal</p> <p>Nervus Vestibularis</p> <p>Nervus Cochlearis</p> <p>Cochlea</p>
		 <p>Palatine tonsil</p> <p>Lingual tonsil</p> <p>Foliate papillae</p> <p>Filiform papillae</p> <p>Circumvallate papillae</p> <p>Fungiform papillae</p>