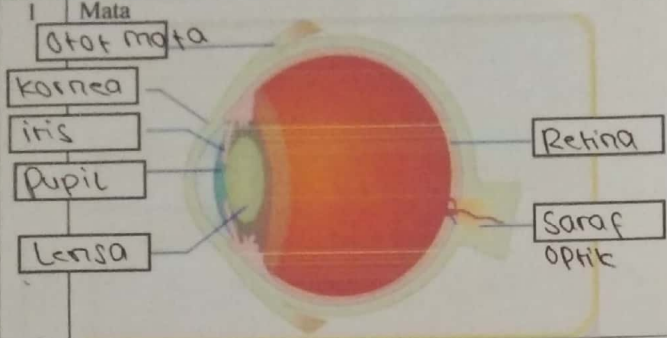
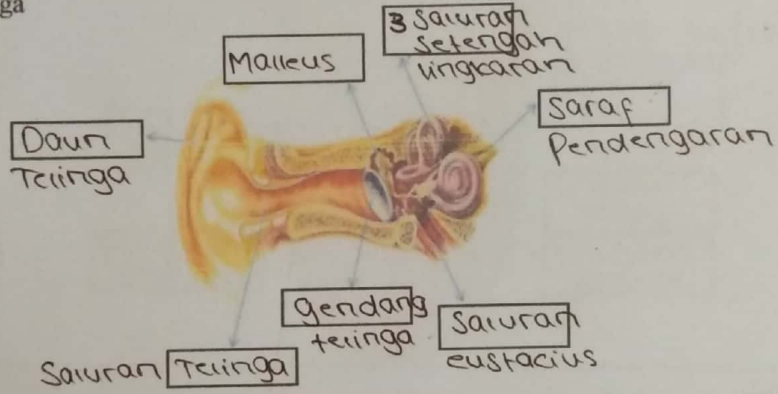
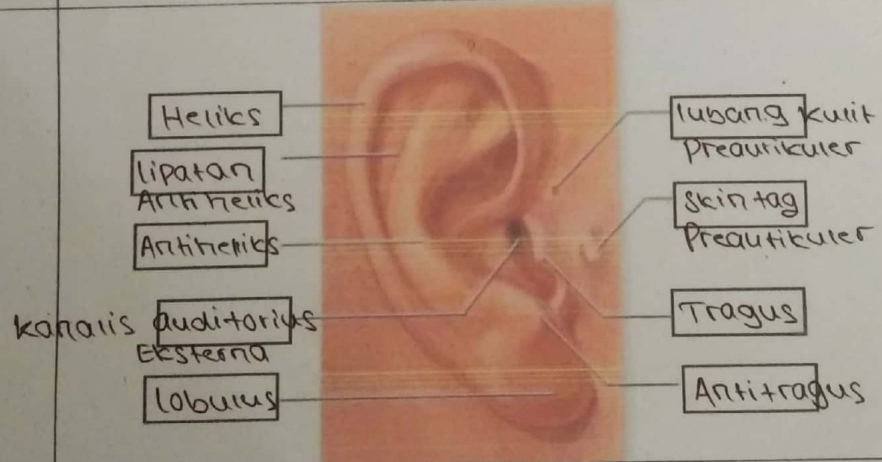


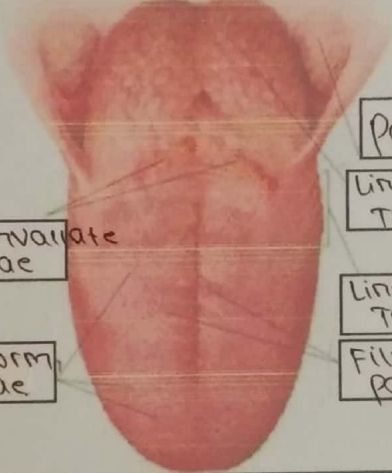
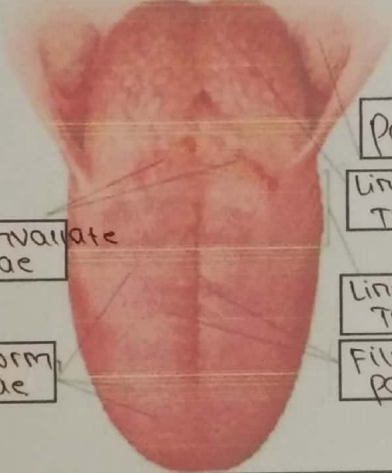


WORKSHEETS (LEMBAR KERJA)

Mata Kuliah	: Anatomi
Materi	: Anatomi Panca Indra
NIM>Nama Mahasiswa	: 2110101120 / EVA NOVITA

No	Keterangan	Pembahasan
1	Mata	 <p>Otot mata</p> <p>kornea</p> <p>iris</p> <p>Pupil</p> <p>Lensa</p> <p>Retina</p> <p>Saraf optik</p>
	Telinga	 <p>Daun Telinga</p> <p>Malleus</p> <p>3 Sauran setengah lingkaran</p> <p>Saraf Pendengaran</p> <p>Gendang telinga</p> <p>Sauran Telinga</p> <p>Sauran eustacius</p>
		 <p>Heliks</p> <p>lipatan Antiheliks</p> <p>Antiheliks</p> <p>kanalis auditorius Eksterna</p> <p>Lobulus</p> <p>lubang kulit Preaurikuler</p> <p>skin tag Preaurikuler</p> <p>Tragus</p> <p>Antitragus</p>

No	Keterangan	Pembahasan
	 <p>Semicular canals</p> <p>Semicular canals</p> <p>Vestibulus</p>	 <p>Semicular canals</p> <p>Vestibular nerve</p> <p>cochlear nerve</p> <p>Cochlea</p>
	 <p>Circumvallate papillae</p> <p>Fungi form papillae</p>	 <p>Palatine tonsil</p> <p>Lingual tonsil</p> <p>Lingual tonsil</p> <p>Fili form papillae</p>