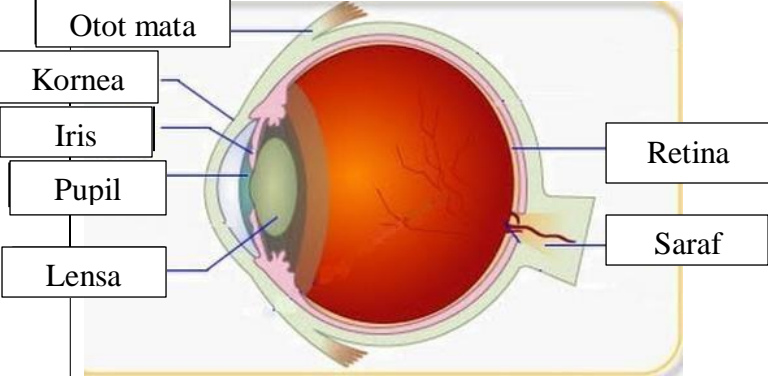
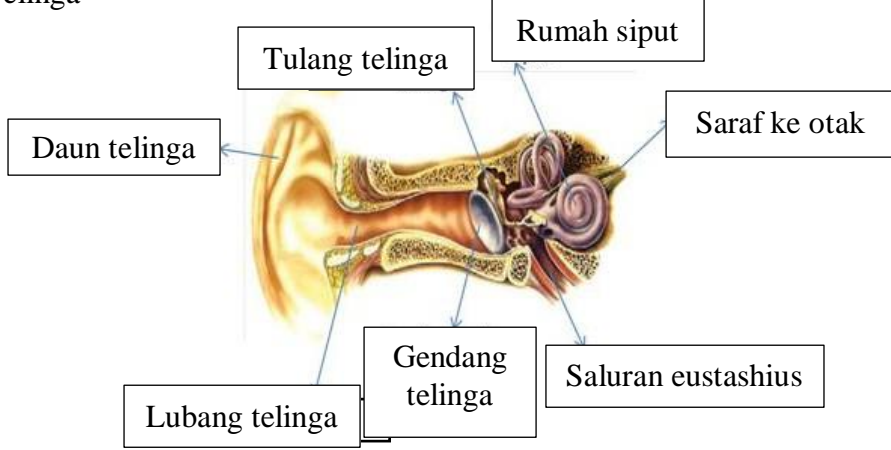
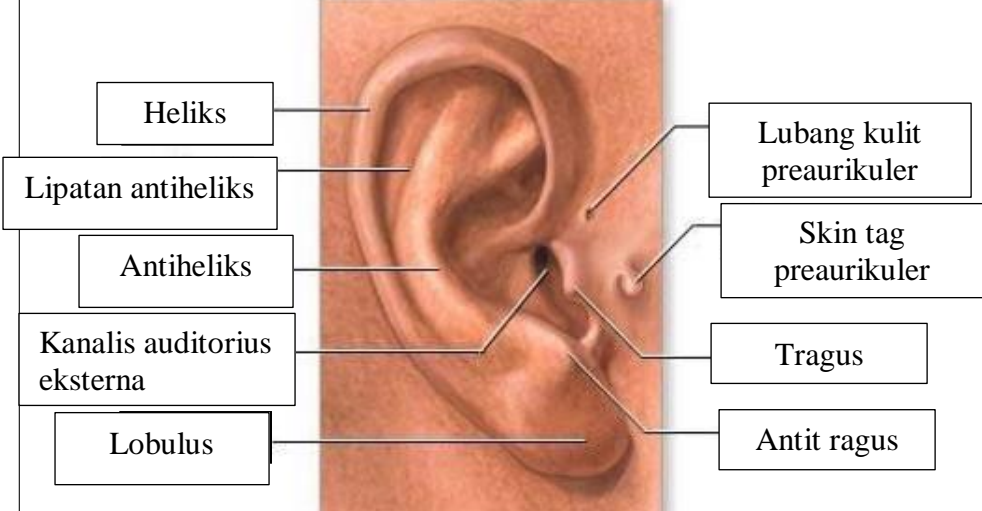
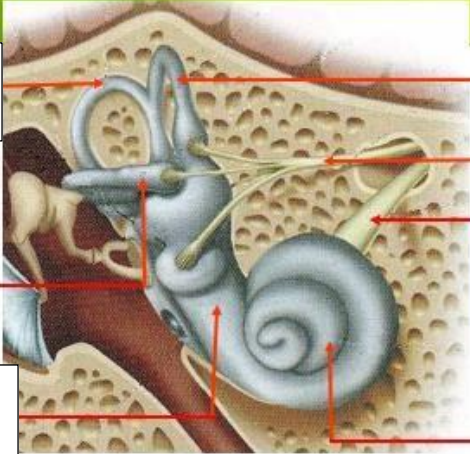
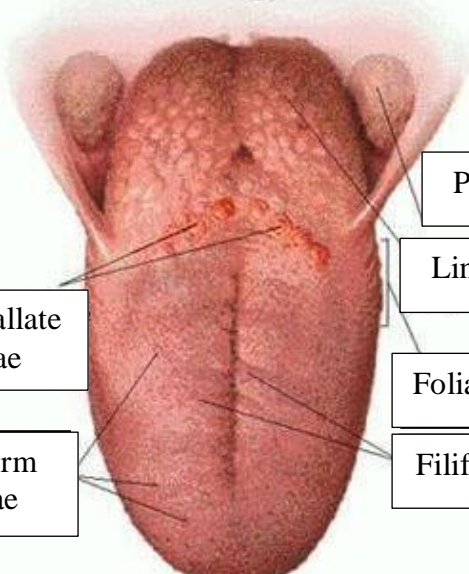


WORKSHEETS (LEMBAR KERJA)

Mata Kuliah	: Anatomi
Materi	: Anatomi Panca Indra
NIM>Nama Mahasiswa	: 2110101076 Deya Devi Noventa Anggraini

No	Keterangan	Pembahasan
1	<p>Mata</p> 	
	<p>Telinga</p> 	
		

No	Keterangan	Pembahasan
	<p data-bbox="272 315 472 405">Semicircular duct</p> <p data-bbox="236 488 472 577">Semicircular duct lateral</p> <p data-bbox="261 640 493 730">Vestibula</p>	 <p data-bbox="995 315 1219 405">Semicircular duct anterior</p> <p data-bbox="995 439 1219 528">Vestibular nerve</p> <p data-bbox="995 555 1219 645">Cochlea nerve</p> <p data-bbox="995 651 1219 730">Cochlea</p>
	<p data-bbox="443 1032 675 1122">Circumvallate papillae</p> <p data-bbox="443 1167 675 1256">Fungiform papillae</p>	 <p data-bbox="1011 898 1259 965">Palatine tonsil</p> <p data-bbox="1011 987 1235 1055">Lingual tonsil</p> <p data-bbox="979 1099 1227 1167">Foliate papillae</p> <p data-bbox="979 1178 1251 1245">Filiform papillae</p>