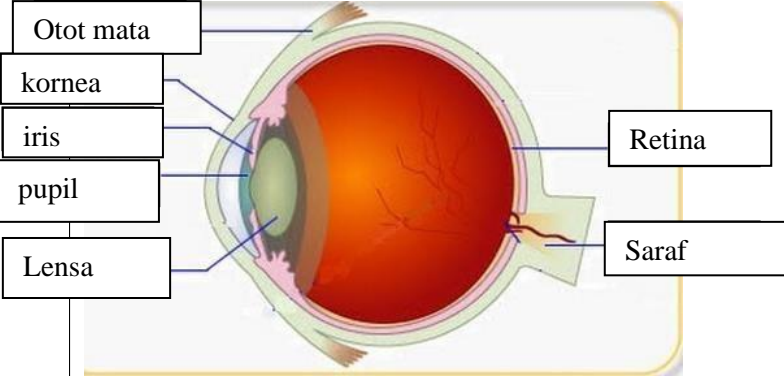
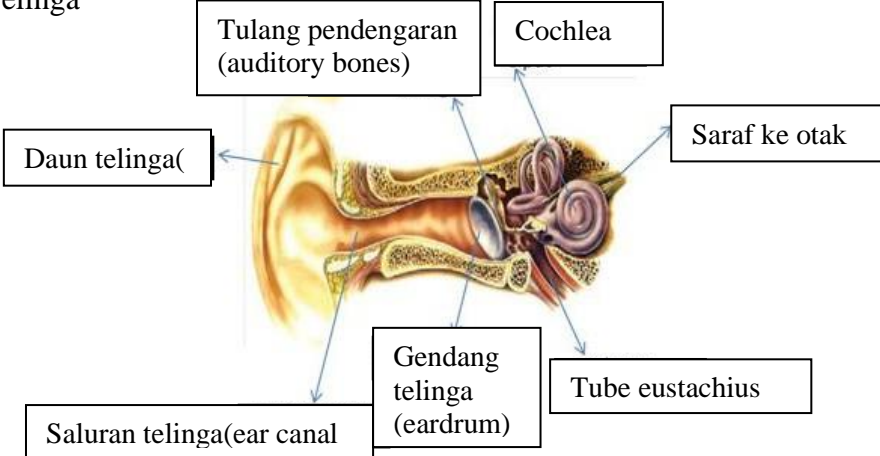
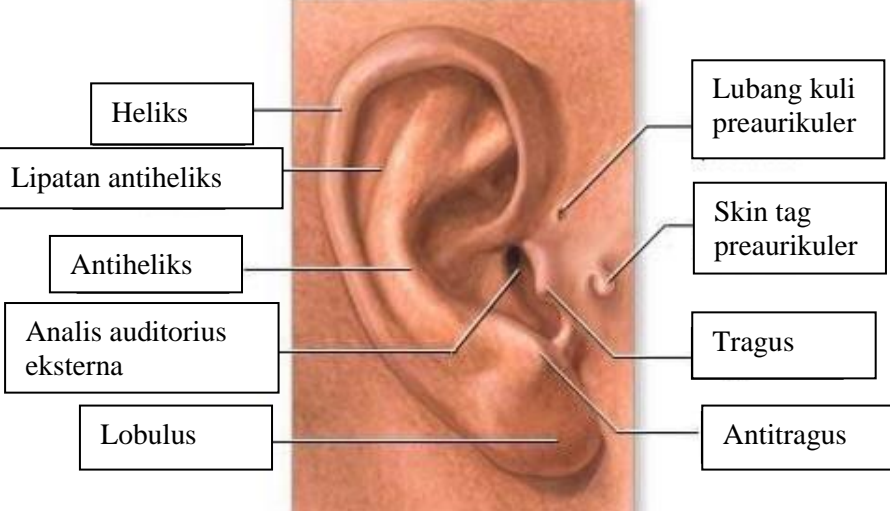
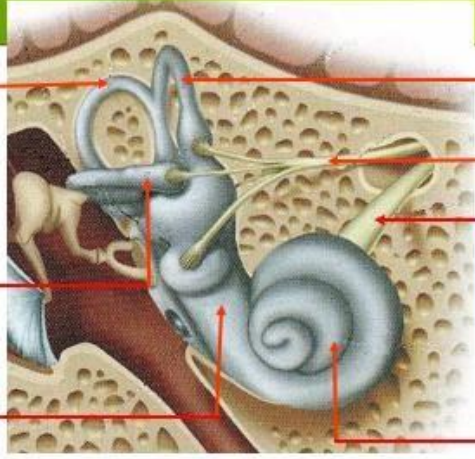
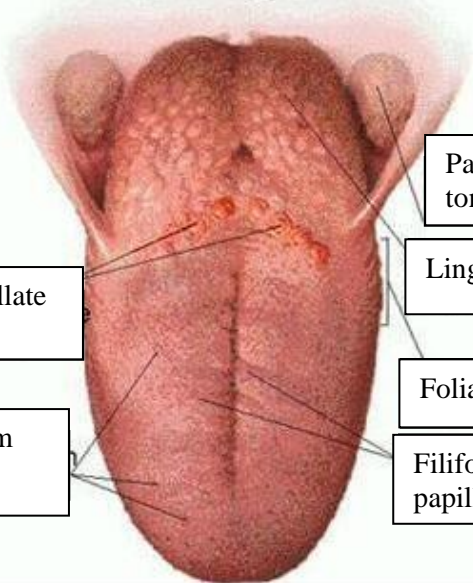


WORKSHEETS (LEMBAR KERJA)

Mata Kuliah	: Anatomi
Materi	: Anatomi Panca Indra
NIM>Nama Mahasiswa	: MARIANA ULFA_2110101111

No	Keterangan	Pembahasan
1	<p>Mata</p> 	
	<p>Telinga</p> 	
		

No	Keterangan	Pembahasan
	<div data-bbox="268 300 464 427" style="border: 1px solid black; padding: 2px;">Posterior semicircular canal</div> <div data-bbox="268 472 464 600" style="border: 1px solid black; padding: 2px;">Lateral semicircular canal</div> <div data-bbox="268 663 464 741" style="border: 1px solid black; padding: 2px;">Vestibuli</div>	 <div data-bbox="991 277 1187 400" style="border: 1px solid black; padding: 2px;">Superior semicircular canal</div> <div data-bbox="991 443 1187 539" style="border: 1px solid black; padding: 2px;">Nervus vestibularis</div> <div data-bbox="991 551 1187 651" style="border: 1px solid black; padding: 2px;">Nervus cochlearis</div> <div data-bbox="991 663 1187 728" style="border: 1px solid black; padding: 2px;">Cochlea</div>
	<div data-bbox="448 1003 671 1099" style="border: 1px solid black; padding: 2px;">Circumvallate papillae</div> <div data-bbox="448 1144 671 1256" style="border: 1px solid black; padding: 2px;">Fungiform papillae</div>	 <div data-bbox="1007 875 1214 965" style="border: 1px solid black; padding: 2px;">Palatine tonsil</div> <div data-bbox="1007 976 1246 1055" style="border: 1px solid black; padding: 2px;">Lingual tonsil</div> <div data-bbox="1007 1088 1225 1167" style="border: 1px solid black; padding: 2px;">Foliate papillae</div> <div data-bbox="1007 1178 1193 1256" style="border: 1px solid black; padding: 2px;">Filiform papillae</div>