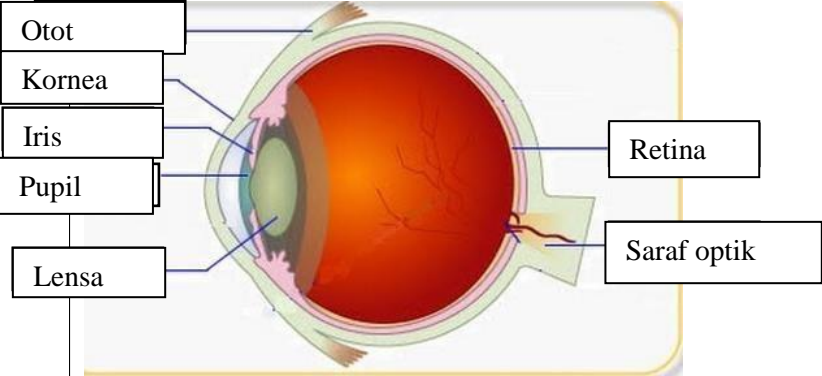
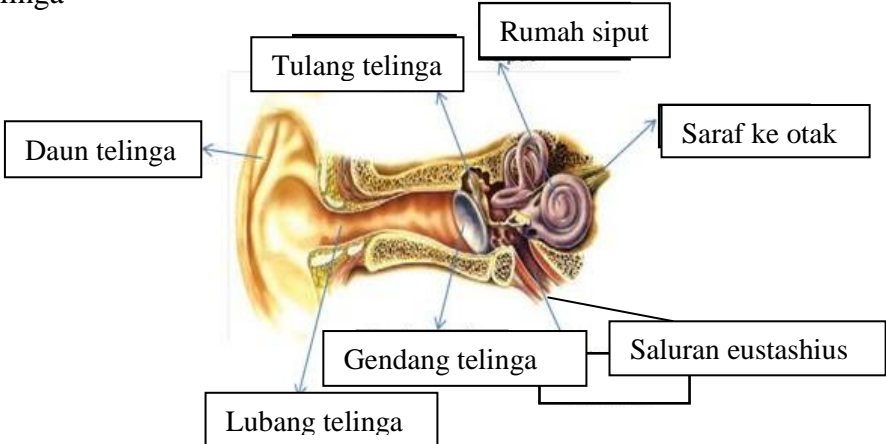
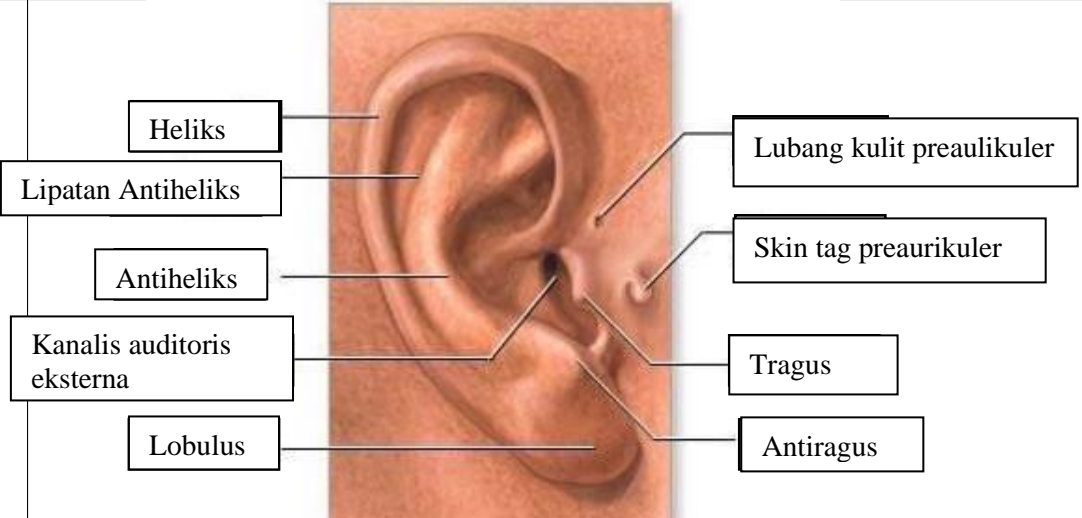
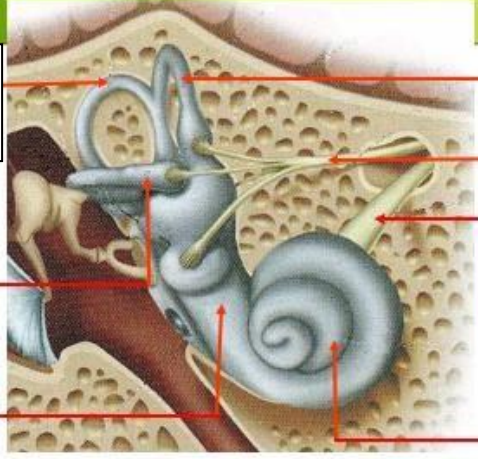
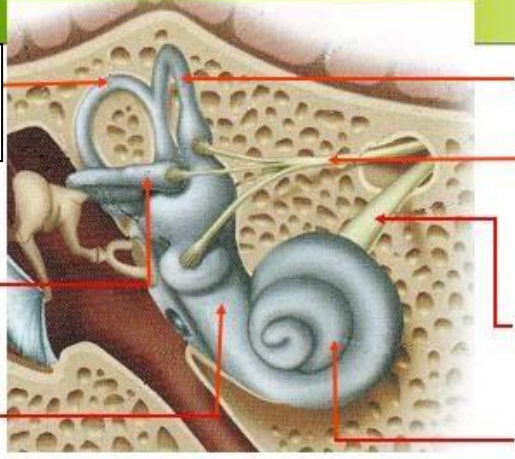
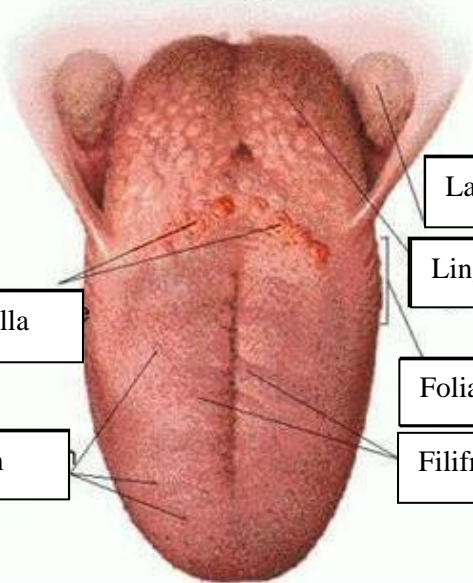
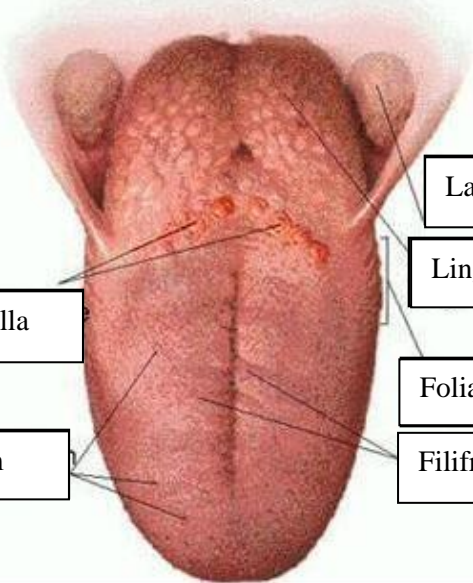


WORKSHEETS (LEMBAR KERJA)

Mata Kuliah	: Anatomi
Materi	: Anatomi Panca Indra
NIM>Nama Mahasiswa	: 2110101073/ Anjeli Sauri

No	Keterangan	Pembahasan
1	<p>Mata</p> 	
	<p>Telinga</p> 	
		

No	Keterangan	Pembahasan
	 <p data-bbox="268 322 475 434">Semioisoulas Candals</p> <p data-bbox="245 488 456 582">Vestibulcus complax</p> <p data-bbox="225 658 456 725">Tingkap bundar</p>	 <p data-bbox="1002 331 1331 421">Semicircules cluct within anterios semicor</p> <p data-bbox="991 450 1295 573">1. Malicus 2. Incus 3. Stapes</p> <p data-bbox="1002 584 1211 645">Saraf kolea</p> <p data-bbox="1002 667 1323 725">Konklec (rumah siput)</p>
	 <p data-bbox="344 1032 673 1099">Circumvallate papilla</p> <p data-bbox="384 1173 660 1240">Papil fungiform</p>	 <p data-bbox="1002 898 1382 965">Langit-langit tenggorokan</p> <p data-bbox="1002 987 1241 1048">Lingual tonsil</p> <p data-bbox="1002 1099 1252 1167">Foliate papillae</p> <p data-bbox="1002 1178 1241 1245">Filiform papillae</p>