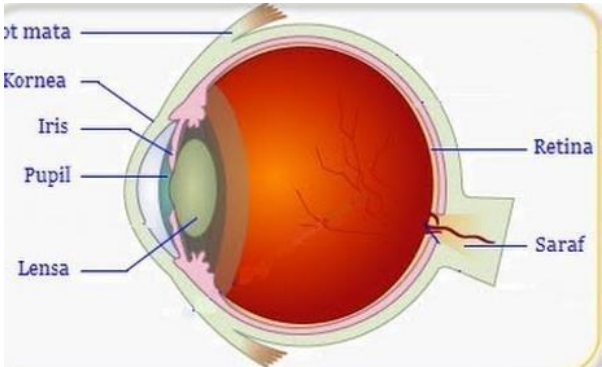

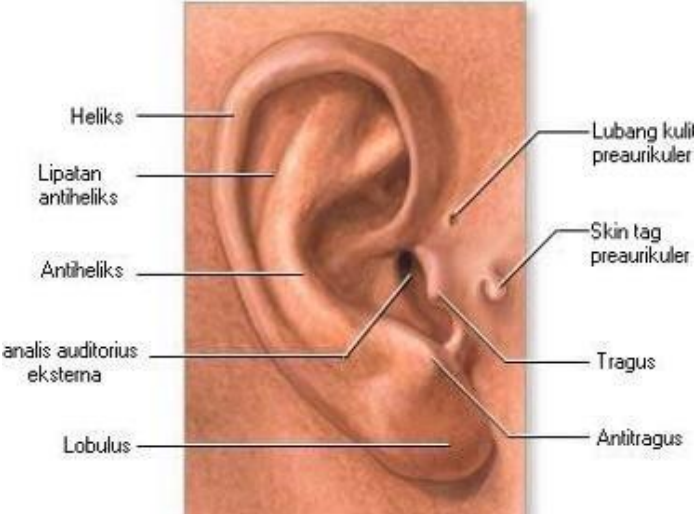

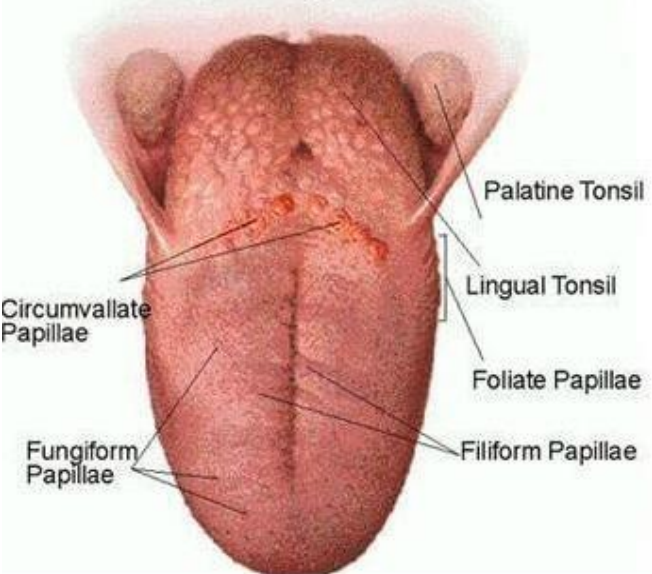


<b>Mata Kuliah</b>	: <b>Anatomi</b>
<b>Materi</b>	: <b>Anatomi Panca Indra</b>
<b>NIM&gt;Nama Mahasiswa</b>	: 2110101117/ sani ulfa widiyana

**WORKSHEETS (LEMBAR KERJA)**

No	Keterangan	Pembahasan
1	<p>Mata</p> 	
	<p>Telinga</p> 	
		

No	Keterangan	Pembahasan
	<p>Posterior semicircular canal</p> <p>Lateral semicircular canal</p> <p>Vestibuli</p>	 <p>Superior semicircular canal</p> <p>Nervus Vestibularis</p> <p>Nervus Cochlearis</p> <p>Cochlea</p>
		 <p>Palatine Tonsil</p> <p>Lingual Tonsil</p> <p>Foliate Papillae</p> <p>Filiform Papillae</p> <p>Fungiform Papillae</p> <p>Circumvallate Papillae</p>