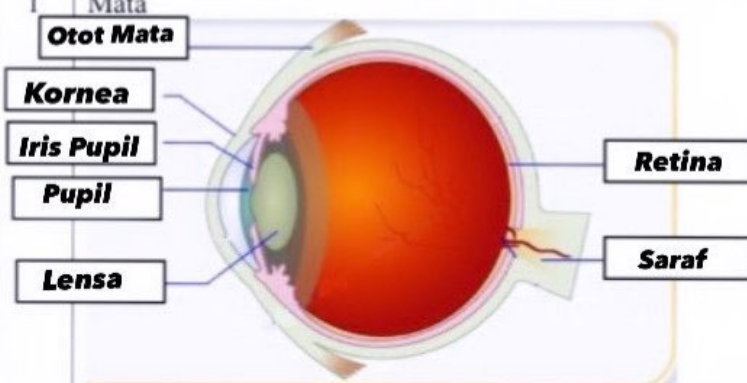

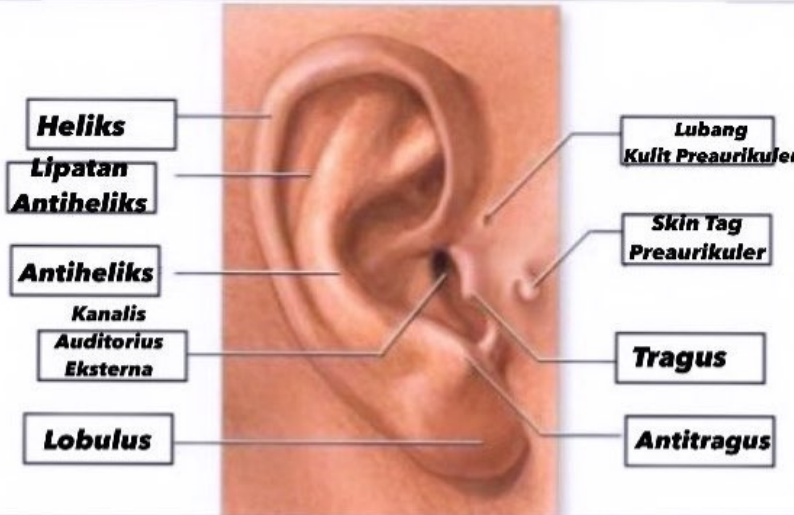


WORKSHEETS (LEMBAR KERJA)

Mata Kuliah	: Anatomi
Materi	: Anatomi Panca Indra
NIM>Nama Mahasiswa	: 2110101071,Putri Ratna Sari Dewi

No	Keterangan	Pembahasan
1	Mata	 <p>Diagram of the human eye showing internal structures. Labels include: Otot Mata (Eye Muscle), Kornea (Cornea), Iris Pupil (Iris/Pupil), Pupil, Lensa (Lens), Retina, and Saraf (Nerve).</p>
	Telinga	 <p>Diagram of the middle ear showing the ossicles and associated structures. Labels include: 1. Daun Telinga (Ear Pinna), 2. Lubang Telinga (Ear Canal), 3. Gendang Telinga (Eardrum), 4. Saluran Eustachius (Eustachian Tube), 5. Saraf ke Otak (Nerve to Brain), 6. Rumah Siput (Cochlea), and 7. Tulang Telinga (Ear Bones).</p>
		 <p>Photograph of a human ear with anatomical labels. Labels include: Heliks (Helix), Lipatan Antiheliks (Antihelical Fold), Antiheliks (Antihelix), Kanalis Auditorius Eksterna (External Auditory Canal), Lobulus (Lobule), Lubang Kulit Preaurikuler (Preauricular Skin Pore), Skin Tag Preaurikuler (Preauricular Skin Tag), Tragus, and Antitragus.</p>

No	Keterangan	Pembahasan
----	------------	------------

