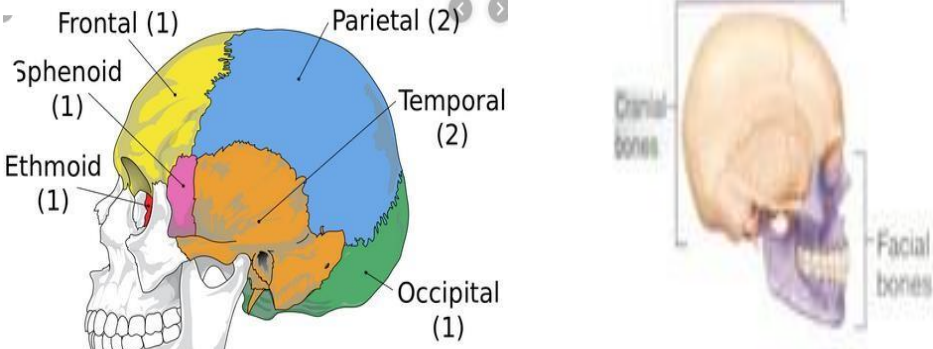
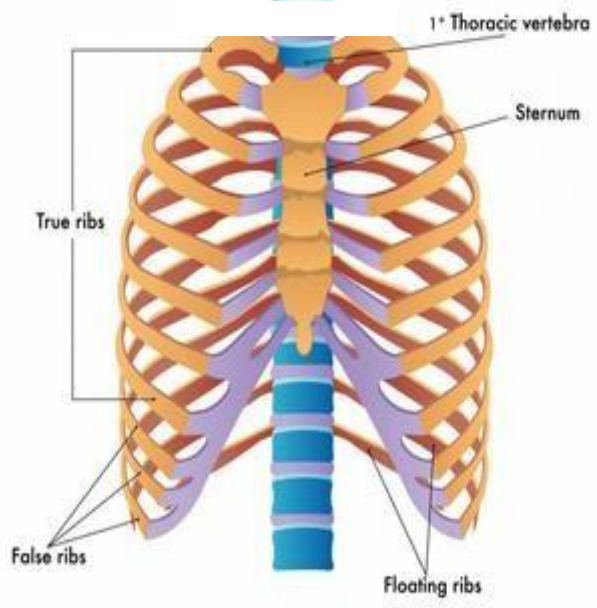
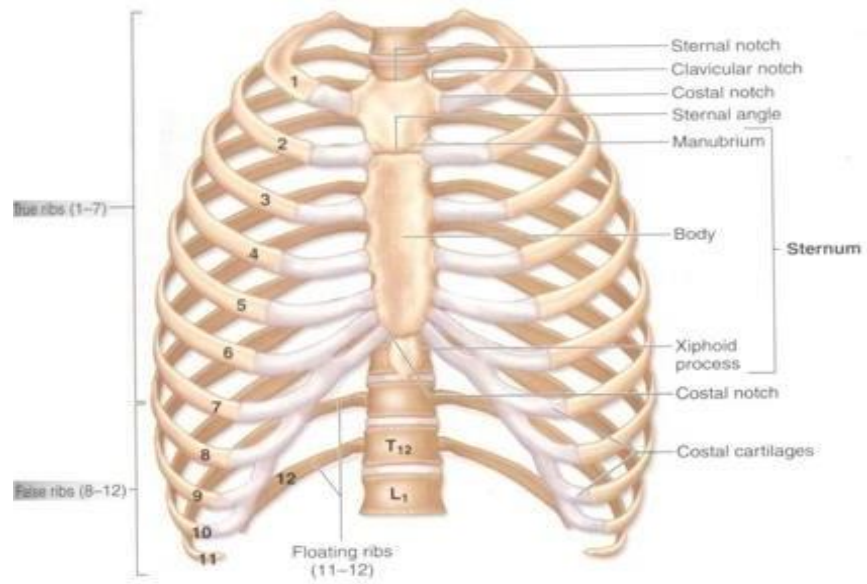
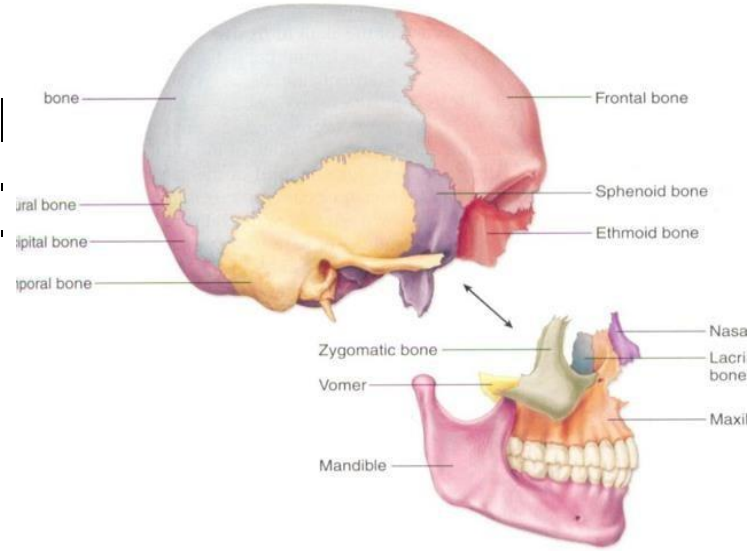


**WORKSHEETS (LEMBAR KERJA)**

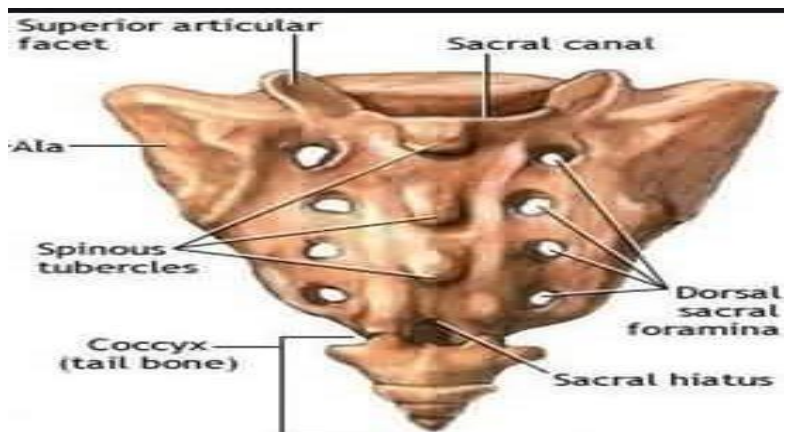
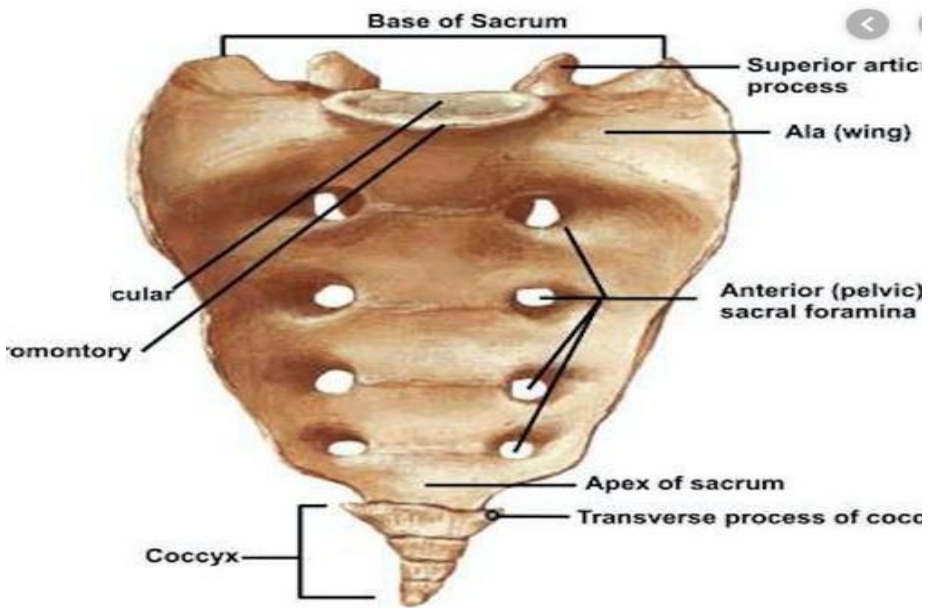
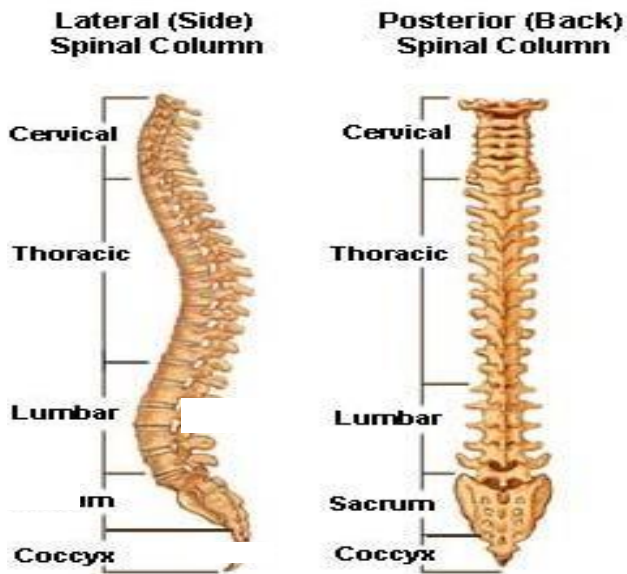
|                              |                                      |
|------------------------------|--------------------------------------|
| <b>Mata Kuliah</b>           | : <b>Anatomi</b>                     |
| <b>Materi</b>                | : <b>Musculoskeletal</b>             |
| <b>NIM&gt;Nama Mahasiswa</b> | : <b>2110101090/AZIZAH PUSPASARI</b> |

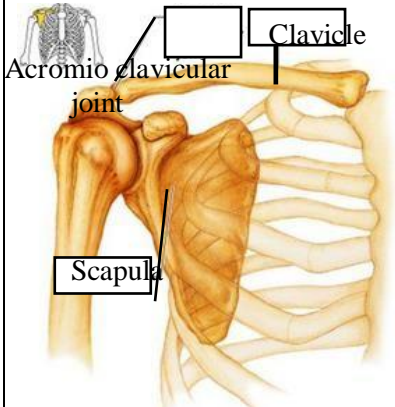
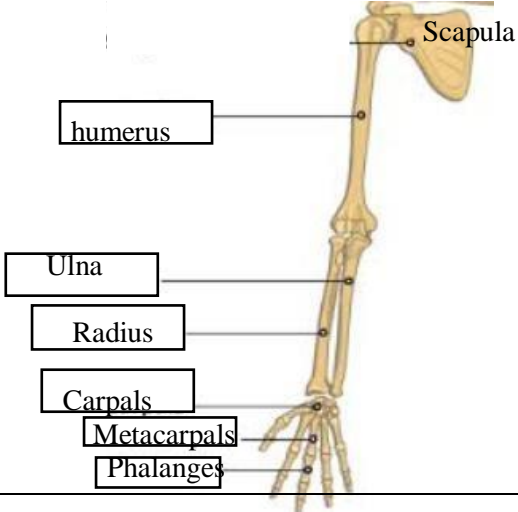
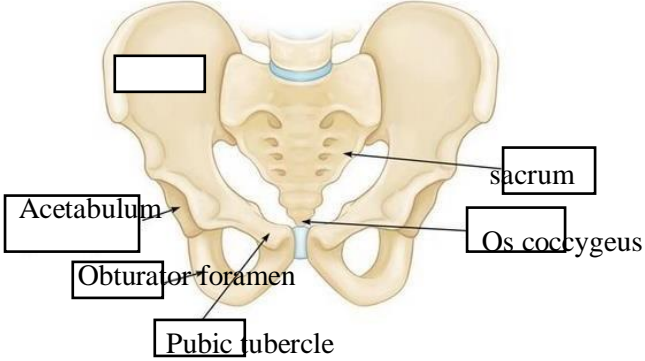
| No             | Keterangan                                                                                                                                                                                                                                                                                                                                                                                                                                                                                                   | Pembahasan     |                      |               |                                     |      |                  |           |                        |        |                  |  |
|----------------|--------------------------------------------------------------------------------------------------------------------------------------------------------------------------------------------------------------------------------------------------------------------------------------------------------------------------------------------------------------------------------------------------------------------------------------------------------------------------------------------------------------|----------------|----------------------|---------------|-------------------------------------|------|------------------|-----------|------------------------|--------|------------------|--|
| 1              | Jumlah tulang manusia 206<br>Tulang Terdiri atas :<br>tulang tengkorak/cranium 8 buah, tulang wajah 14 buah, tulang telinga dalam 6 buah, tulang lidah 1 buah, tulang dada 25 buah, tulang belakang (vertebrae) dan pelvis 26 buah, tulang ekstremitas atas 64 buah, tulang ekstremitas bawah 62 buah.                                                                                                                                                                                                       |                |                      |               |                                     |      |                  |           |                        |        |                  |  |
| 2              | Jelaskan klasifikasi Tulang menurut bentuknya :<br>1.) Tulang longa (tulang panjang) yaitu tulang yang ukuran panjangnya terbesar, contoh os humerus<br>2.) Ossa brevia (tulang pendek) yaitu tulang yang ketiga kurannya kira-kira samabesar, contoh ossa carpi.<br>3.) Ossa plana (tulang gepeng/pipih) yaitu tulang yang ukuran lebarnya terbesar, contoh os parietale.<br>4.) Ossa irregular (tulang tak beraturan), contoh os sphenoidale.<br>5.) Ossa pneumatica (tulang berongga), contoh os maxilla. |                |                      |               |                                     |      |                  |           |                        |        |                  |  |
| 3              | <table border="1" style="width: 100%; border-collapse: collapse;"> <thead> <tr> <th style="width: 50%;">Axial Skeleton</th> <th style="width: 50%;">Apendicular sceleton</th> </tr> </thead> <tbody> <tr> <td>Skull, Sterum</td> <td>Supporting (scapula and collarbone)</td> </tr> <tr> <td>Ribs</td> <td>Upper ilmb bones</td> </tr> <tr> <td>Vertebrae</td> <td>Supporting bones (hip)</td> </tr> <tr> <td>Sacrum</td> <td>Lower limb bones</td> </tr> </tbody> </table>                                  | Axial Skeleton | Apendicular sceleton | Skull, Sterum | Supporting (scapula and collarbone) | Ribs | Upper ilmb bones | Vertebrae | Supporting bones (hip) | Sacrum | Lower limb bones |  |
| Axial Skeleton | Apendicular sceleton                                                                                                                                                                                                                                                                                                                                                                                                                                                                                         |                |                      |               |                                     |      |                  |           |                        |        |                  |  |
| Skull, Sterum  | Supporting (scapula and collarbone)                                                                                                                                                                                                                                                                                                                                                                                                                                                                          |                |                      |               |                                     |      |                  |           |                        |        |                  |  |
| Ribs           | Upper ilmb bones                                                                                                                                                                                                                                                                                                                                                                                                                                                                                             |                |                      |               |                                     |      |                  |           |                        |        |                  |  |
| Vertebrae      | Supporting bones (hip)                                                                                                                                                                                                                                                                                                                                                                                                                                                                                       |                |                      |               |                                     |      |                  |           |                        |        |                  |  |
| Sacrum         | Lower limb bones                                                                                                                                                                                                                                                                                                                                                                                                                                                                                             |                |                      |               |                                     |      |                  |           |                        |        |                  |  |
| 4              | Jelaskan fungsi sendi dan contohnya :<br>Sendi berfungsi berupa menghubungkan dua tulang, memberi struktur, serta membantu oto untuk menggerakkan tulang.<br>Contohnya : sendi sinartrosis, sendi amfiartrosis, dan sendi diartrosis.                                                                                                                                                                                                                                                                        |                |                      |               |                                     |      |                  |           |                        |        |                  |  |
| 5              |  <p align="center"><b>8 Cranial Bones</b></p>                                                                                                                                                                                                                                                                                                                                                                            |                |                      |               |                                     |      |                  |           |                        |        |                  |  |

| No | Keterangan | Pembahasan |
|----|------------|------------|
|----|------------|------------|



| No | Keterangan | Pembahasan |
|----|------------|------------|
|----|------------|------------|



| No | Keterangan                                                                                                                                                                                                            | Pembahasan                                                                                                                                                   |
|----|-----------------------------------------------------------------------------------------------------------------------------------------------------------------------------------------------------------------------|--------------------------------------------------------------------------------------------------------------------------------------------------------------|
|    | <p>Pectoral/shoulder girdle</p>  <p>Clavicle</p> <p>Acromioclavicular joint</p> <p>Scapula</p>                                       |                                                                                                                                                              |
|    | <p>Upper limb bones</p>  <p>Scapula</p> <p>humerus</p> <p>Ulna</p> <p>Radius</p> <p>Carpals</p> <p>Metacarpals</p> <p>Phalanges</p> |                                                                                                                                                              |
|    | <p>Hip/pelvis</p>  <p>Acetabulum</p> <p>Obturator foramen</p> <p>Pubic tubercle</p> <p>sacrum</p> <p>Os coccygeus</p>              | <div data-bbox="999 1294 1337 1688" style="border: 1px solid black; padding: 10px;"> <p>Os coxae terdiri dari Os ilium, os ischium, dan Os pubis.</p> </div> |

| No | Keterangan | Pembahasan |
|----|------------|------------|
|----|------------|------------|

