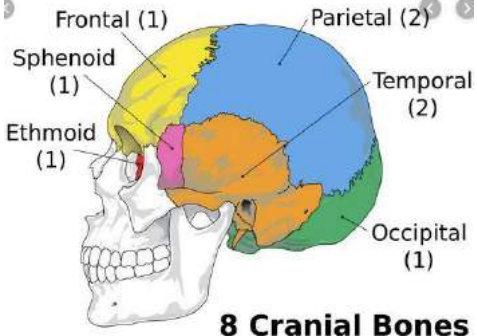
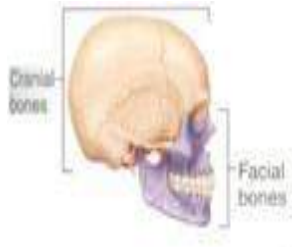


WORKSHEETS (LEMBAR KERJA)

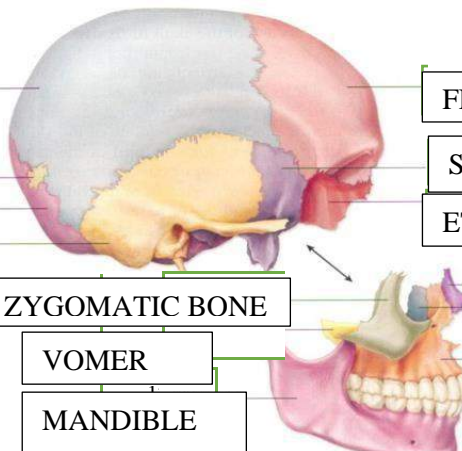
Mata Kuliah	: Anatomi
Materi	: Musculoskeletal
NIM>Nama Mahasiswa	: 2110101112/mufidah

No	Keterangan	Pembahasan												
1	Jumlah tulang manusia 206 Tulang	<p>Terdiri atas :</p> <ul style="list-style-type: none"> -Tulang tengkorak/cranium 8 buah - Tulang wajah 14 buah - Tulang telinga dalam 6 buah -Tulang lidah 1 buah - Tulang dada 25 buah -Tulang belakang (vertebrae) dan pelvis 26 buah - Tulang ekstremitas atas 64 buah -Tulang ekstremitas bawah 62 												
2	Jelaskan klasifikasi Tulang menurut bentuknya	<ul style="list-style-type: none"> • Os longum (tulang panjang) misalnya : humerus, tibia, femur, dsb. • Os brevis (tulang pendek) misalnya : ossa carpalia, ossa tarsalia • Os planum (tulang pipih) misalnya : scapula, cranii • Os pneumaticum (tulang berongga) misalnya : os maxillaris, ossis ethimoidalis • Os irreguler (tidak beraturan) misalnya : vertebra. • Os sesamoidea, tulang yang terdapat pada persedian, misalnya : patella dan beberapa tulang pada persendian jari-jari tangan dan kaki. 												
3	Sistem skeletal	<table border="1" style="width: 100%; border-collapse: collapse;"> <thead> <tr> <th style="width: 50%; text-align: center;">Axial sceleton</th> <th style="width: 50%; text-align: center;">Apendicular sceleton</th> </tr> </thead> <tbody> <tr> <td>Skull, Sterum</td> <td></td> </tr> <tr> <td>Ribs</td> <td>Supporting (scapula and collarbone)</td> </tr> <tr> <td>Vertebrae</td> <td>Upper limb bones</td> </tr> <tr> <td>Sacrum</td> <td>Supporting bones (hip)</td> </tr> <tr> <td></td> <td>Lower limb bones</td> </tr> </tbody> </table>	Axial sceleton	Apendicular sceleton	Skull, Sterum		Ribs	Supporting (scapula and collarbone)	Vertebrae	Upper limb bones	Sacrum	Supporting bones (hip)		Lower limb bones
Axial sceleton	Apendicular sceleton													
Skull, Sterum														
Ribs	Supporting (scapula and collarbone)													
Vertebrae	Upper limb bones													
Sacrum	Supporting bones (hip)													
	Lower limb bones													

4	Jelaskan fungsi sendidan contohnya	Sendi berfungsi berupa menghubungkan dua tulang, memberi struktur, serta membantu oto untuk menggerakkan tulang. Contohnya : sendi sinartrosis, sendi amfiartrosis, dan sendi diartrosis.
---	------------------------------------	--

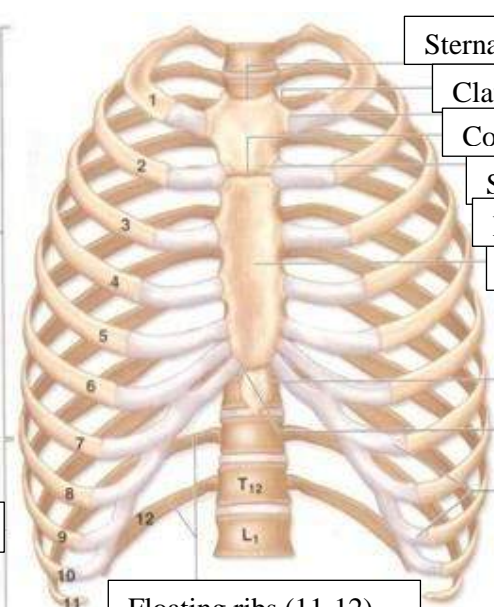
5	<p>Cranium</p>  <p>8 Cranial Bones</p>	
---	--	---

nm	No	Keterangan	Pembahasan
----	----	------------	------------



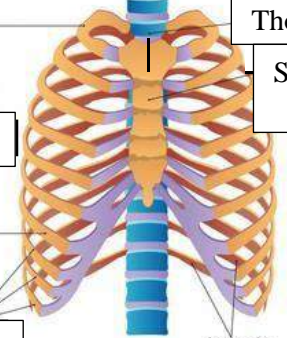
Labels for skull bones:

- BONE
- SATERAL BONE
- OCCIPITAL BOONE
- TEMPORAL BONE
- ZYGOMATIC BONE
- VOMER
- MANDIBLE
- FRONTAL BOME
- SPEHENOID BONE
- ETHMOID BONE
- NASAL BONE
- LACRIMAL BONE
- MAXILLA



Labels for rib cage parts:

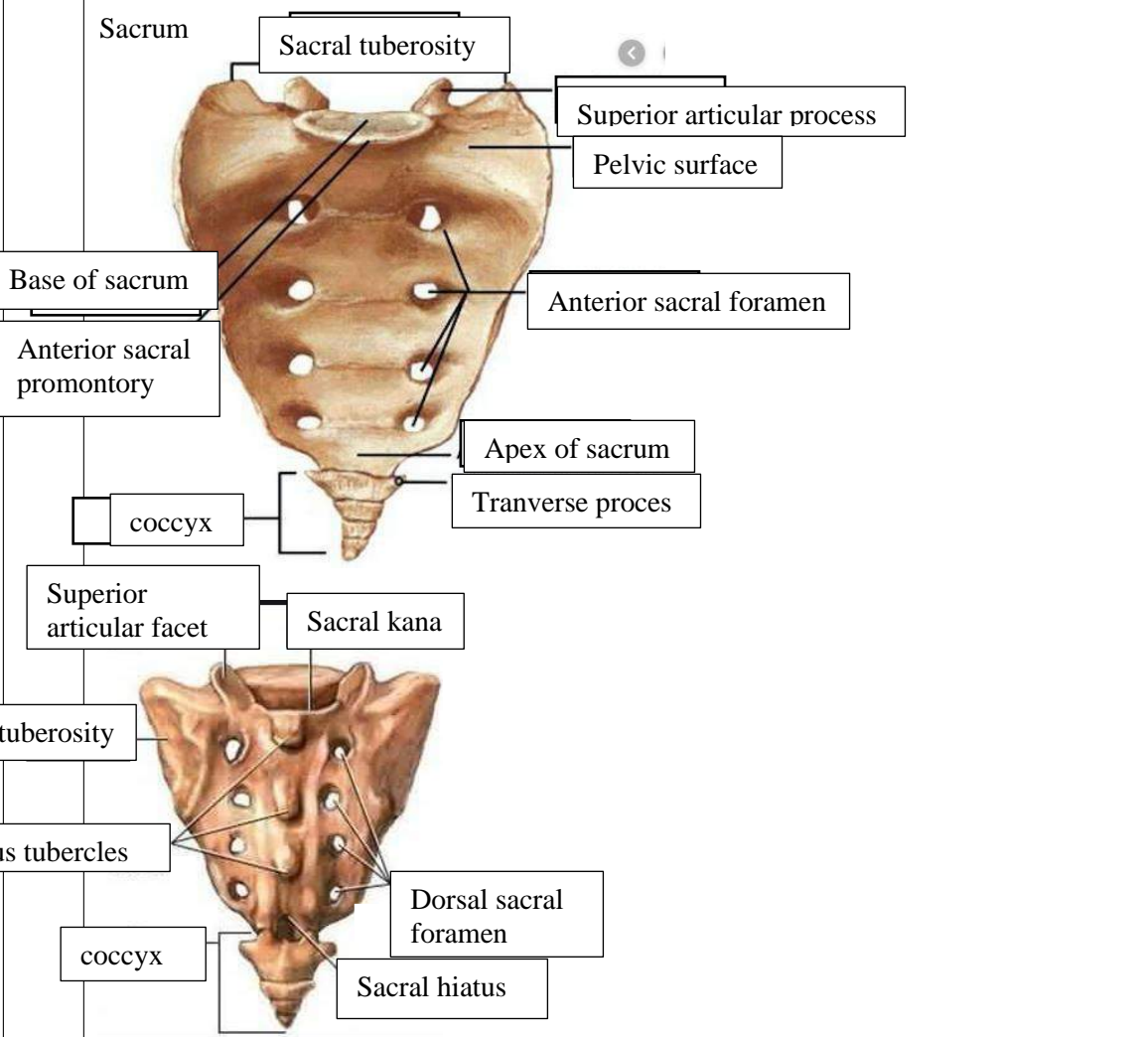
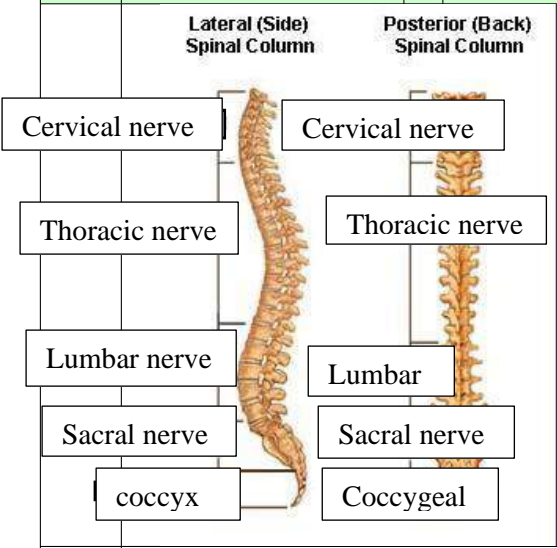
- True ribs
- False ribs (6-12)
- Floating ribs (11-12)
- Sternal Notch
- Clavicular Noteh
- Costal Noteh
- Sternal Angel
- Manubrium
- Body
- Sternum
- Shiphoid process
- Costal notch
- Costal cartilage

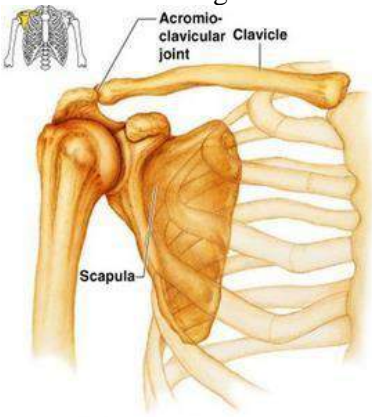
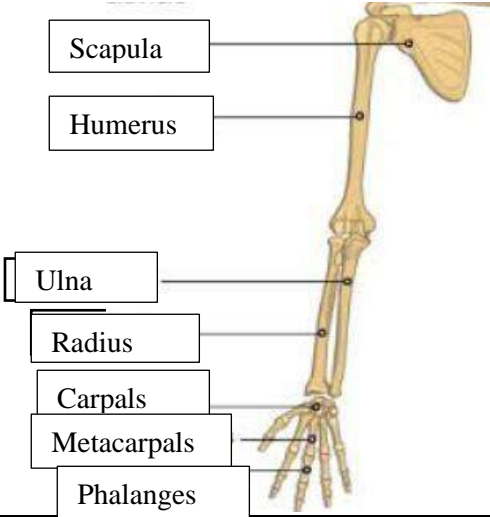
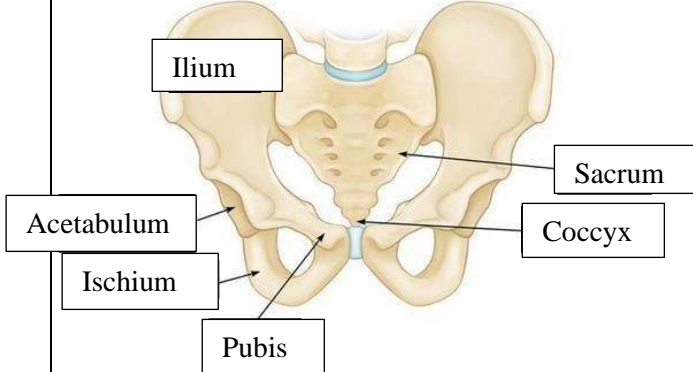


Labels for rib cage connections:

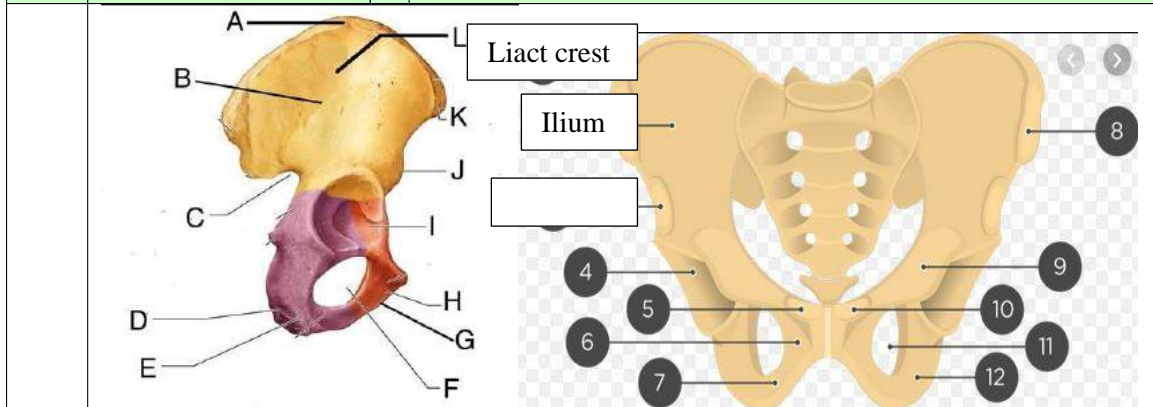
- True ribs
- False ribs
- Thoracic vertebra
- Sternum

No	Keterangan	Pembahasan
----	------------	------------



No	Keterangan	Pembahasan
	<p>Pectoral/shoulder girdle</p>  <p>Labels: Acromioclavicular joint, Clavicle, Scapula</p>	
	<p>Upper limb bones</p>  <p>Labels: Scapula, Humerus, Ulna, Radius, Carpals, Metacarpals, Phalanges</p>	
	<p>Hip/pelvis</p>  <p>Labels: Ilium, Sacrum, Coccyx, Acetabulum, Ischium, Pubis</p>	<p>Os coxae terdiri dari Ilium, Sacrum, Coccyx, Acetabulum, Ischium dan Pubis</p>

No	Keterangan	Pembahasan
----	------------	------------



Lower limb bones

