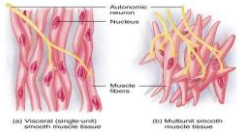
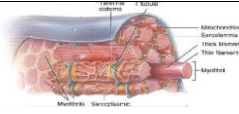
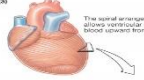
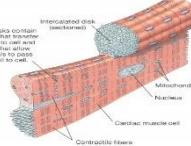
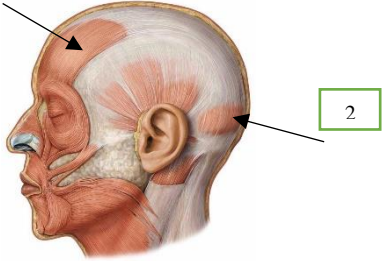
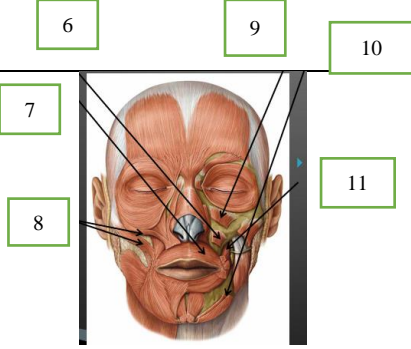
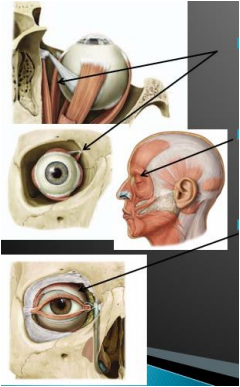
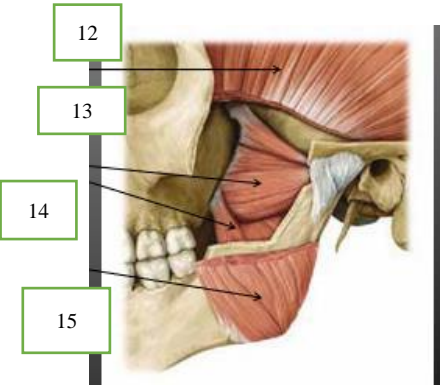
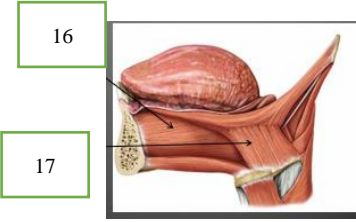
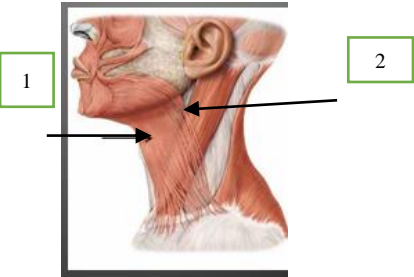
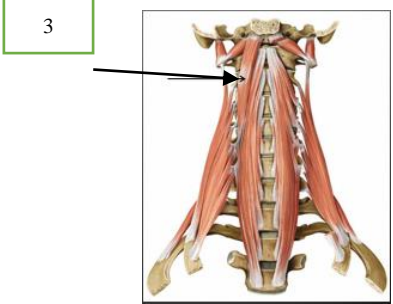
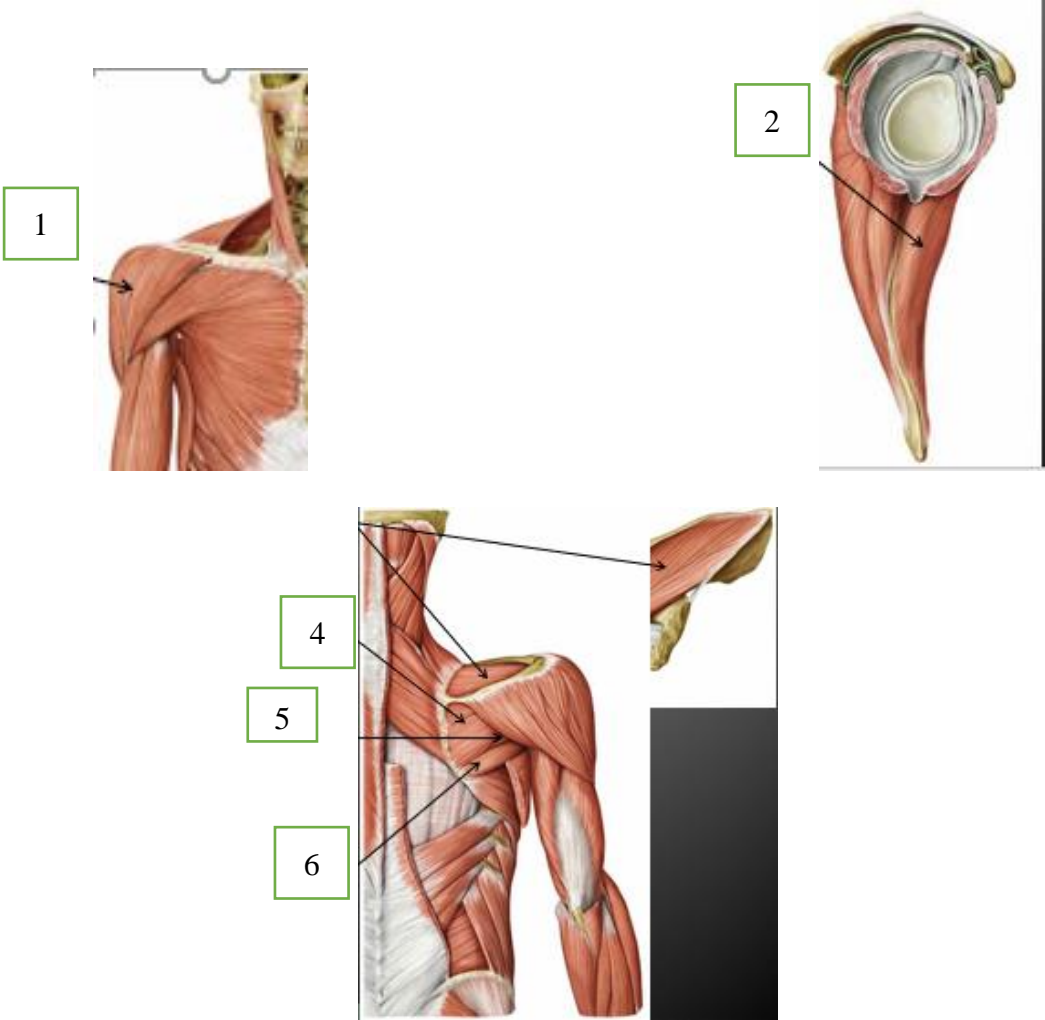




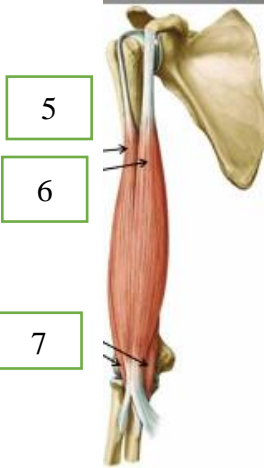


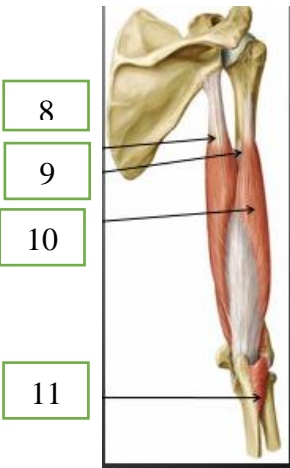
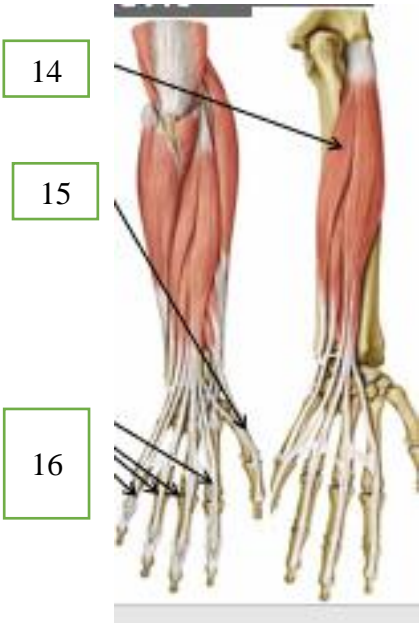
WORKSHEETS (LEMBAR KERJA)

Mata Kuliah	: Anatomi
Materi	: Musculoskeletal
NIM>Nama Mahasiswa	:


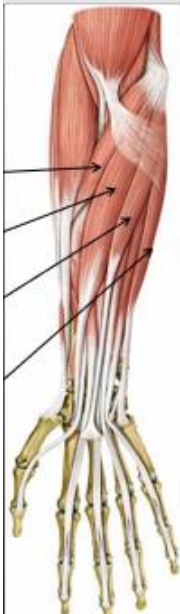
No	Keterangan	Pembahasan
1	Sebutkan struktur otot rangka	: Makroskopik Mikroskopik
2	Jelaskan 1. Axial musculature 2. Appendicular musculature	
3	Sebutkan ciri ciri otot berikut 	:
4		:
5	(a)  The spiral arrangement of ventricular muscle allows ventricular contraction to pump the blood upward from the apex of the heart. (b)  Intercalated disks contain desmosomes that transfer force from cell to cell and gap junctions that allow electrical signals to pass rapidly between cells.	:
6	Jelaskan fungsi otot	
7	Jelaskan otot antagonis dan contohnya	

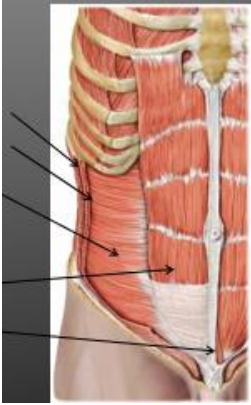
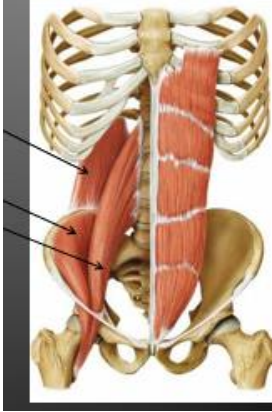
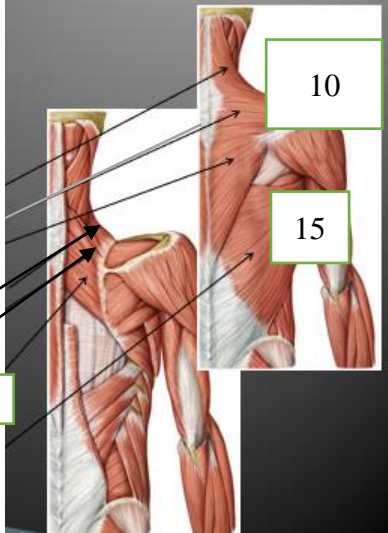
No	Keterangan	Pembahasan
	Jelaskan otot sinergis dan contohnya	
8 Otot wajah	    	
9	Otot leher	 


No	Keterangan	Pembahasan
10	Otot bahu	 <p>The 'Pembahasan' section contains three anatomical illustrations. The top-left illustration shows a lateral view of the right shoulder with a green box labeled '1' and an arrow pointing to the deltoid muscle. The top-right illustration shows a cross-section of the shoulder joint with a green box labeled '2' and an arrow pointing to the deltoid muscle. The bottom-center illustration shows a medial view of the chest and shoulder with three green boxes labeled '4', '5', and '6' and arrows pointing to the pectoralis major, pectoralis minor, and serratus anterior muscles, respectively.</p>
	Otot dada	 <p>The 'Pembahasan' section contains two anatomical illustrations. The left illustration shows a posterior view of the ribcage with a green box labeled '1' and an arrow pointing to the pectoralis major muscle. The right illustration shows a lateral view of the ribcage with a green box labeled '2' and an arrow pointing to the pectoralis minor muscle.</p>

No	Keterangan	Pembahasan
	 <p>3</p>  <p>5</p> <p>6</p> <p>7</p>  <p>12</p> <p>13</p>	 <p>4</p>  <p>8</p> <p>9</p> <p>10</p> <p>11</p>  <p>14</p> <p>15</p> <p>16</p>

No	Keterangan	Pembahasan
----	------------	------------

	 <p>17</p> <p>18</p> <p>19</p> <p>20</p>	 <p>21</p> <p>22</p> <p>23</p> <p>24</p>
--	---	---

<p>Regio abdomen</p>  <p>1</p> <p>2</p> <p>3</p> <p>4</p> <p>5</p>	 <p>6</p> <p>7</p> <p>8</p>  <p>9</p> <p>10</p> <p>11</p> <p>12</p> <p>13</p> <p>14</p> <p>15</p>
--	--

No	Keterangan	Pembahasan
	Regio glutealis	
	Ektermitas inferior	