

WORKSHEETS (LEMBAR KERJA)

Mata Kuliah	: Anatomi
Materi	: Musculoskeletal
NIM>Nama Mahasiswa	: 2110101129/musyarofah

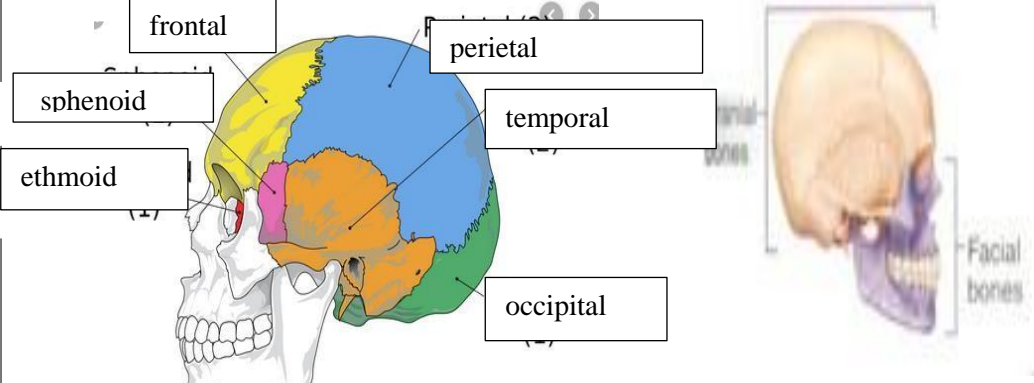
No	Keterangan	Pembahasan
----	------------	------------

1	<p>Jumlah tulang manusia 206 Tulang Terdiri atas :</p> <ul style="list-style-type: none"> tulang tengkorak/cranium 8 buah tulang wajah 14 buah tulang telinga dalam 6 buah tulang lidah 1 buah tulang dada 25 buah tulang belakang (vertebrae) dan pelvis 26 buah tulang ekstremitas atas 64 buah, tulang ekstremitas bawah 62 buah. 	
---	---	--

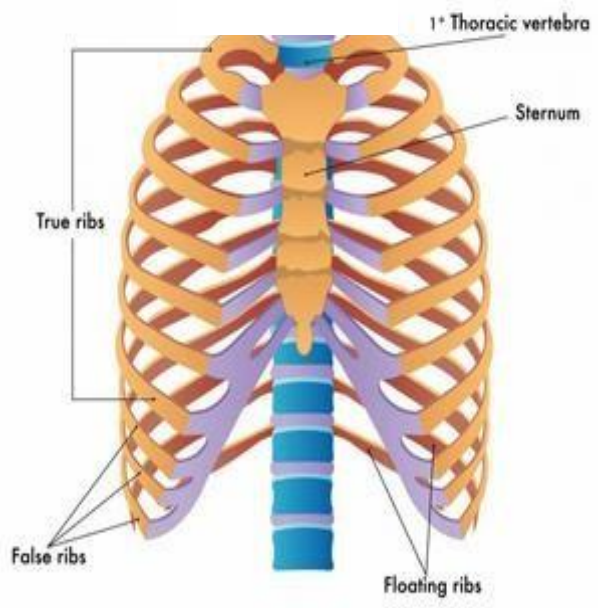
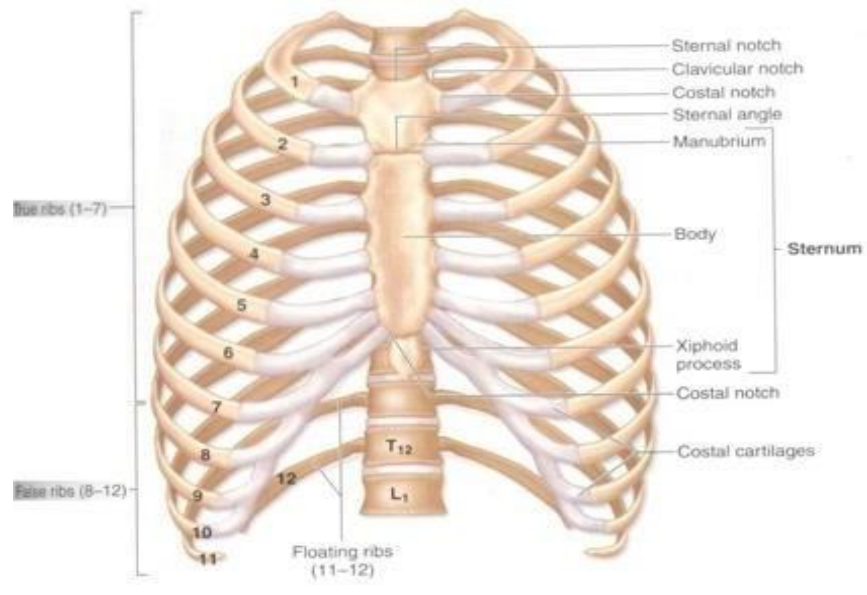
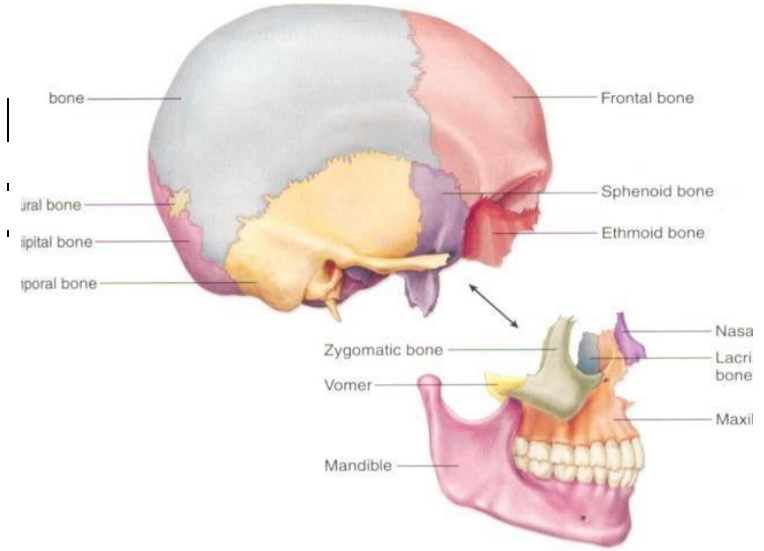
2	<p>Jelaskan klasifikasi Tulang menurut bentuknya :</p> <ol style="list-style-type: none"> 1.) Tulang longa (tulang panjang) yaitu tulang yang ukuran panjangnya terbesar, contoh os humerus 2.) Ossa brevia (tulang pendek) yaitu tulang yang ketiga kurannya kira-kira samabesar, contoh ossa carpi. 3.) Ossa plana (tulang gepeng/pipih) yaitu tulang yang ukuran lebarnya terbesar, contoh os parietale. 4.) Ossa irregular (tulang tak beraturan), contoh os sphenoidale. 5.) Ossa pneumatica (tulang berongga), contoh os maxilla. 	
---	--	--

3	<table border="1" style="width: 100%; border-collapse: collapse;"> <thead> <tr> <th style="width: 50%; text-align: center;">Axial Skeleton</th> <th style="width: 50%; text-align: center;">Apendicular sceleton</th> </tr> </thead> <tbody> <tr> <td>Skull, Sterum</td> <td>Supporting (scapula and collarbone)</td> </tr> <tr> <td>Ribs</td> <td>Upper ilmb bones</td> </tr> <tr> <td>Vertebrae</td> <td>Supporting bones (hip)</td> </tr> <tr> <td>Sacrum</td> <td>Lower limb bones</td> </tr> </tbody> </table>	Axial Skeleton	Apendicular sceleton	Skull, Sterum	Supporting (scapula and collarbone)	Ribs	Upper ilmb bones	Vertebrae	Supporting bones (hip)	Sacrum	Lower limb bones	
Axial Skeleton	Apendicular sceleton											
Skull, Sterum	Supporting (scapula and collarbone)											
Ribs	Upper ilmb bones											
Vertebrae	Supporting bones (hip)											
Sacrum	Lower limb bones											

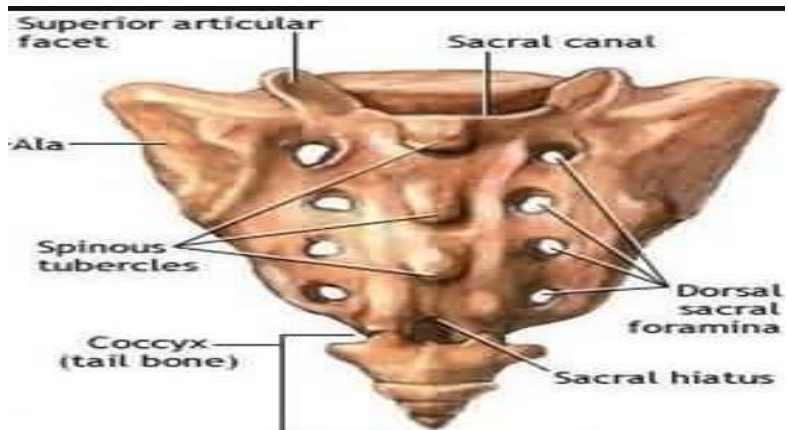
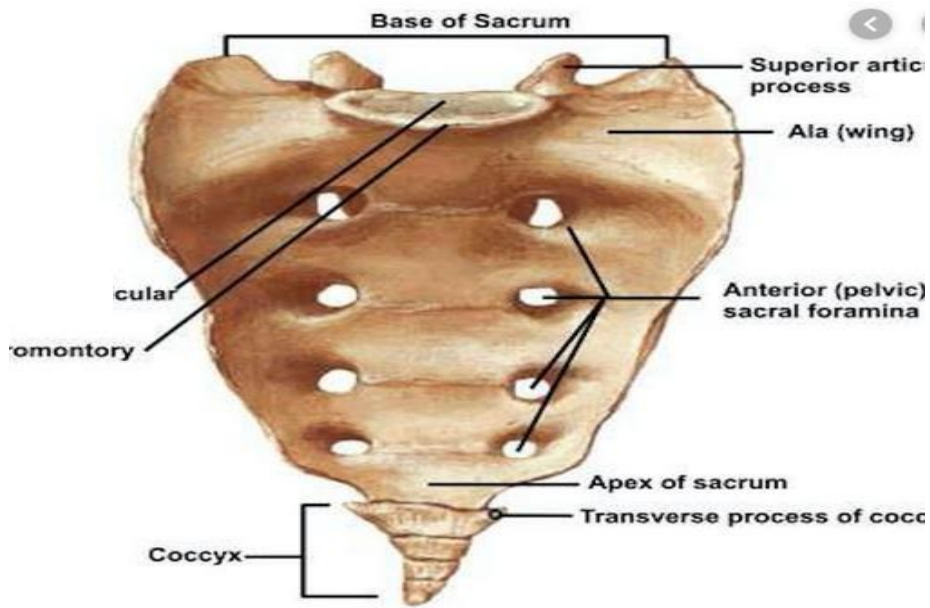
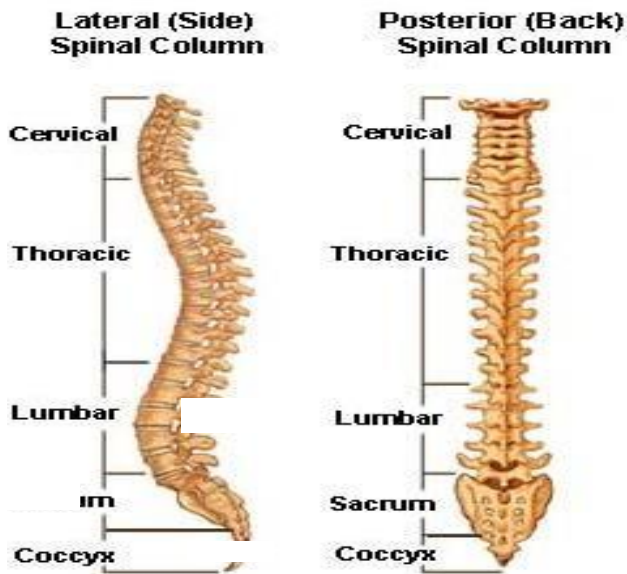
4	<p>Jelaskan fungsi sendi dan contohnya :</p> <p>Sendi berfungsi berupa menghubungkan dua tulang, memberi struktur, serta membantu oto untuk menggerakkan tulang.</p> <p>Contohnya : sendi sinartrosis, sendi amfiartrosis, dan sendi diartrosis.</p>	
---	--	--

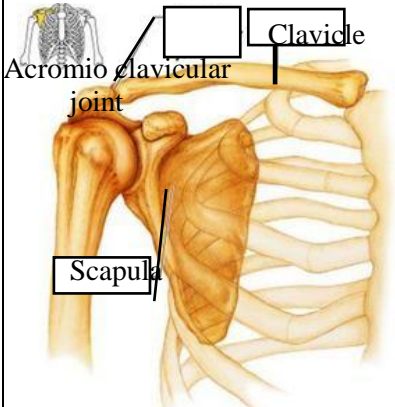
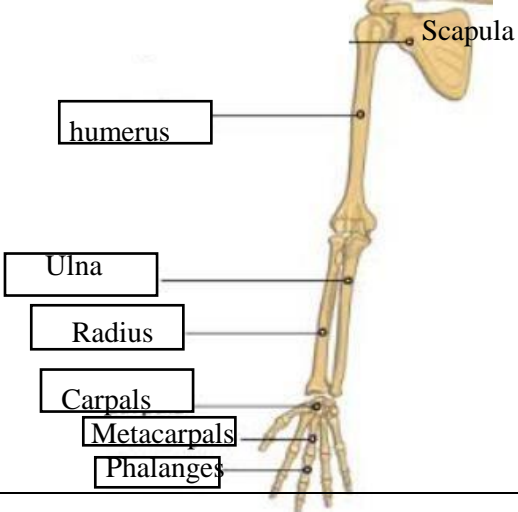
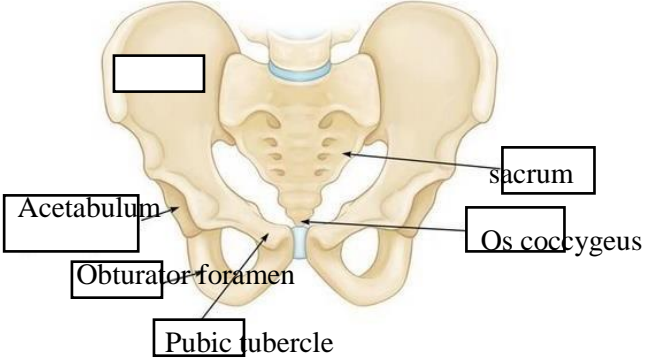
5	 <p>The diagram illustrates the 8 cranial bones of the human skull. The frontal bone is colored yellow, the parietal bone is blue, the temporal bone is orange, and the occipital bone is green. The sphenoid bone is pink and the ethmoid bone is red. The facial bones are shown in purple. Labels with leader lines point to each of these bones.</p>
---	--

No	Keterangan	Pembahasan
----	------------	------------

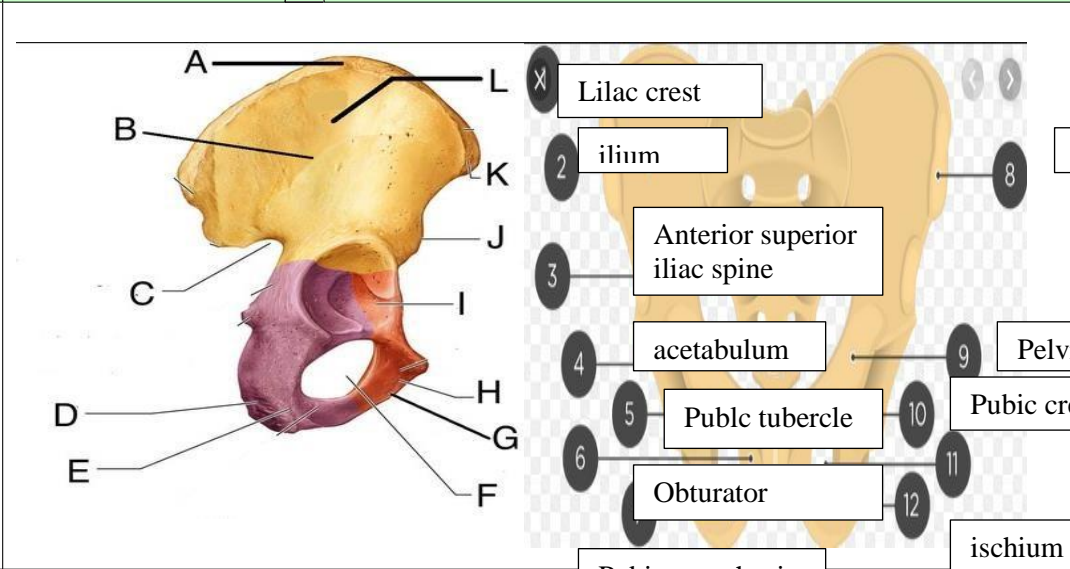


No	Keterangan	Pembahasan
----	------------	------------



No	Keterangan	Pembahasan
	<p>Pectoral/shoulder girdle</p>  <p>Clavicle</p> <p>Acromioclavicular joint</p> <p>Scapula</p>	
	<p>Upper limb bones</p>  <p>Scapula</p> <p>humerus</p> <p>Ulna</p> <p>Radius</p> <p>Carpals</p> <p>Metacarpals</p> <p>Phalanges</p>	
	<p>Hip/pelvis</p>  <p>Acetabulum</p> <p>Obturator foramen</p> <p>Pubic tubercle</p> <p>sacrum</p> <p>Os coccygeus</p>	<div data-bbox="999 1294 1339 1688" style="border: 1px solid black; padding: 10px;"> <p>Os coxae terdiri dari Os ilium, os ischium, dan Os pubis.</p> </div>

No	Keterangan	Pembahasan
----	------------	------------



Lower limb bones

