

No	Keterangan	Pembahasan
----	------------	------------

Ket :

1. Parietal
- 2.
3. Tulang pelipis
4. Tulang rongga telinga
5. Tulang dahi
6. Tulang baji
7. ethmoid
8. Tulang hidung
9. Tulang air mata
10. Rahang atas
11. zygomatik
12. maxilla
13. Tulang rahang bawah

Tulang rusuk sejati

tulang rusuk palsu

Floating ribs

Clavicular notch

manubri

bod v

sternum

Costal notch

Costal cartilages

Tulang rusuk sejati

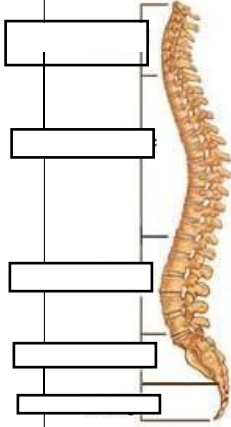
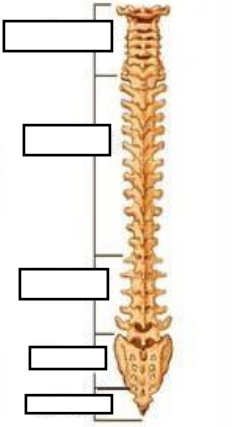
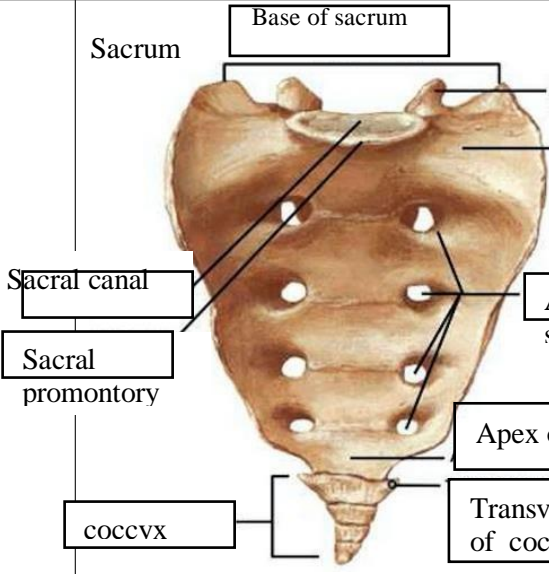
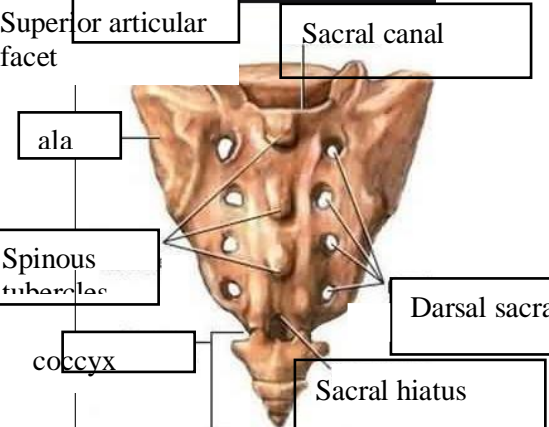
Tulang rusuk melayang

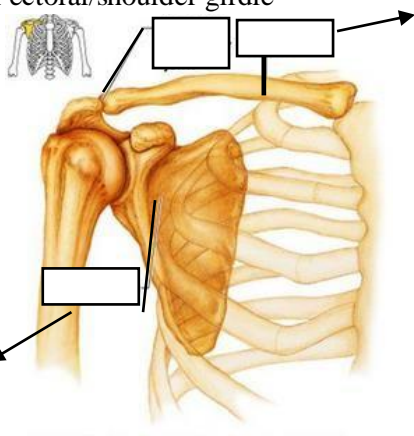
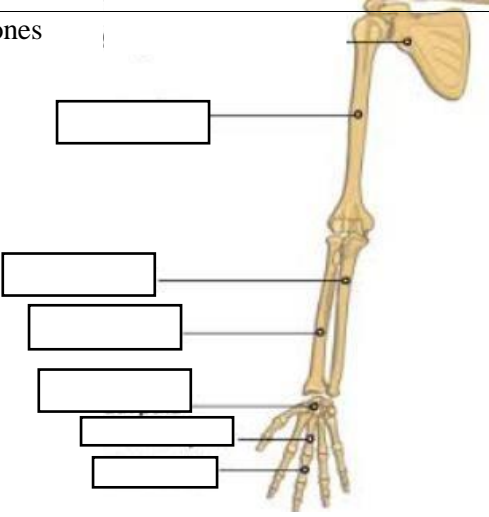
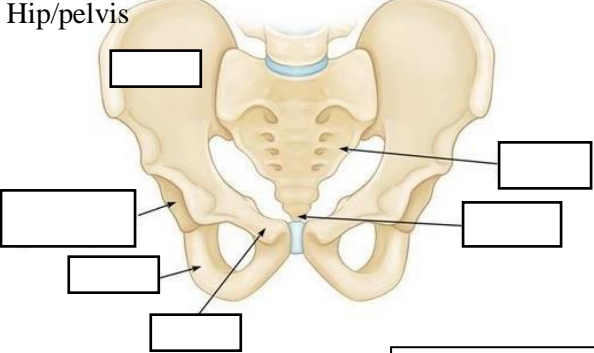
Vertebra

Thoracic vertebra

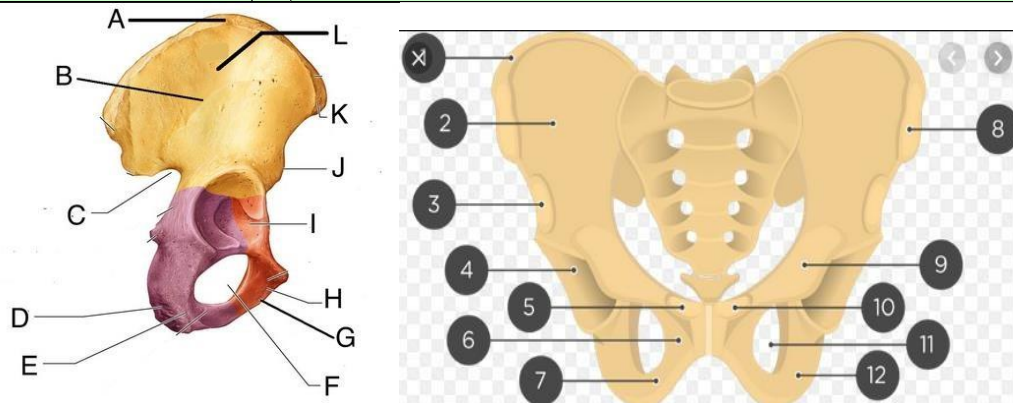
sternum

Tulang rusuk melayang

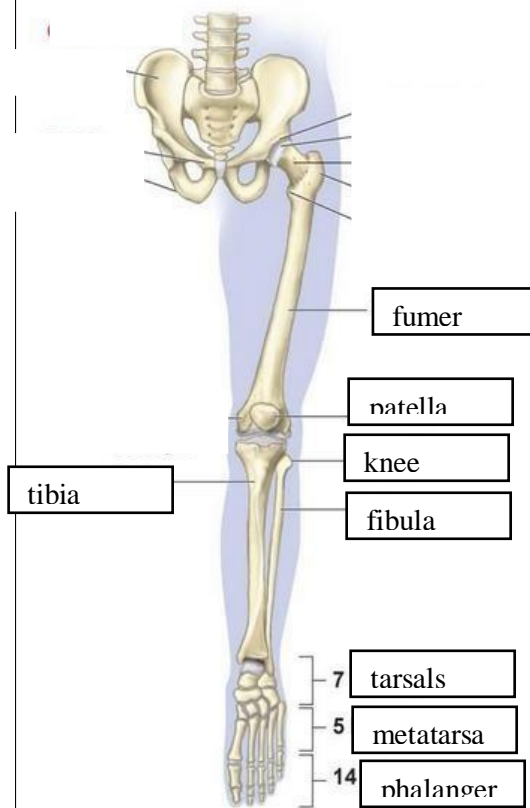
No	Keterangan	Pembahasan
	<div style="display: flex; justify-content: space-around;"> <div style="text-align: center;"> <p>Lateral (Side) Spinal Column</p>  </div> <div style="text-align: center;"> <p>Posterior (Back) Spinal Column</p>  </div> </div>	<p>Ket :</p> <ul style="list-style-type: none"> -tulang leher 7 ruas -tulang punggung 12 ruas -tulang pinggang 12 ruas -tulang sakrum -tulang ekor -cervical -thoracic -lumbar -sacrum -coccyx
		

No	Keterangan	Pembahasan
	<p>Pectoral/shoulder girdle</p>  <p>tulang selangka</p> <p>Tulang belikat</p>	
	<p>Upper limb bones</p> 	<p>Ket :</p> <ul style="list-style-type: none"> -scapula -humerus -ulna -radius -carpals -metacarpals -phalanges
	<p>Hip/pelvis</p> 	<p>Os coxae terdiri dari Os ilium, os ischium dan os pubis</p> <p>Ket :</p> <ul style="list-style-type: none"> -ilium -acetabulum -ischium -pubis -sacrum -coccyx

No	Keterangan	Pembahasan
----	------------	------------



Lower limb bones



Ket :

- A. Intermediate zone iliac crest
- B. Anterior gluteal line
- C. Greater sciatic notch
- D. Body of ischium
- E. Ischial tuberosity
- F. Obturator foramen
- G. Inferior pubic ramus
- H. Obturator crest
- I. Margin(limbus)of acetabulum
- J. Anterior inferior iliac spine
- K. Anterior superior iliac spine
- L. Tuberculum of iliac crest

Ket :

- 1. iliac crest
- 2. Ilium
- 3. Anterior inferior iliac spine
- 4. Acetabulum
- 5. Pubic tubercle
- 6. Pubic symphysis
- 7. Subpubic angle
- 8. The upper front iliac bone
- 9. Lesser sciatic foramen
- 10. Pubis tubercle
- 11. The obturator foramen
- 12. Ischial tuberosity