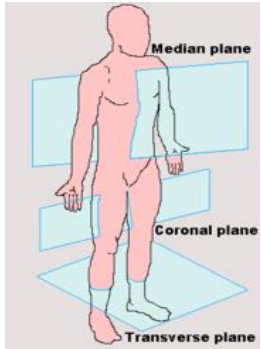
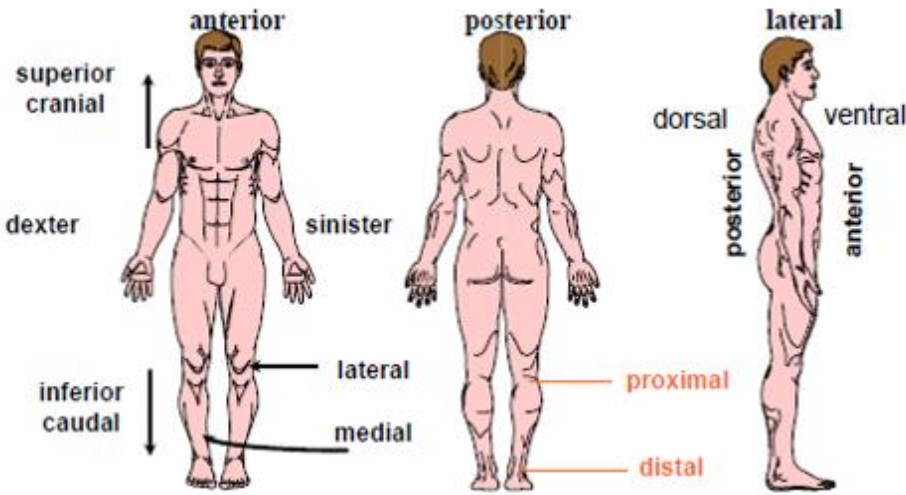
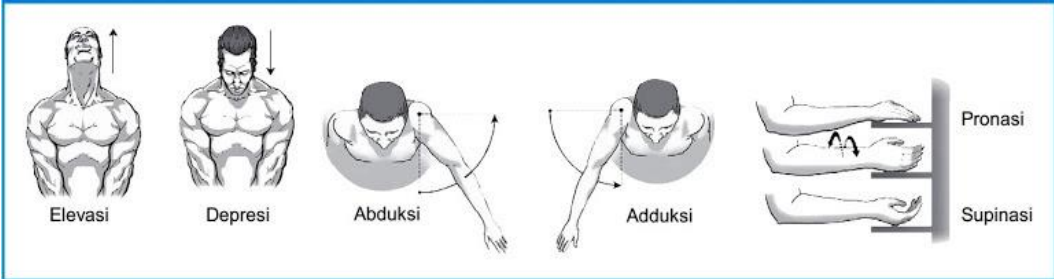
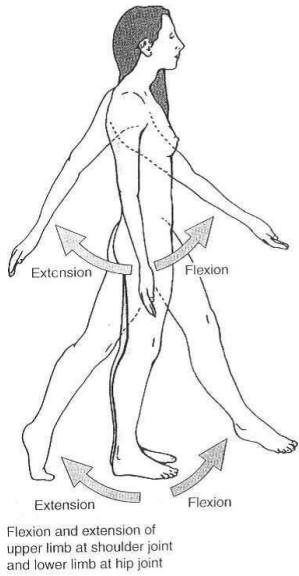
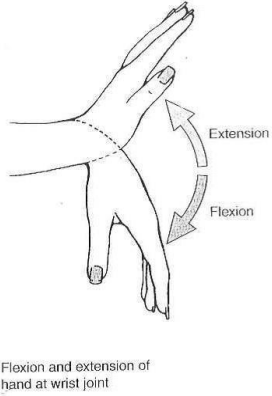
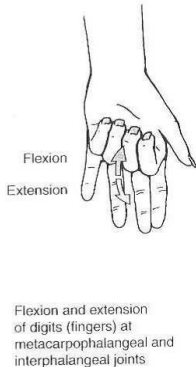


**WORKSHEETS (LEMBAR KERJA)**

<b>Mata Kuliah</b>	<b>: Anatomi</b>
<b>Materi</b>	<b>: Konsep Dasar Anatomi</b>
<b>NIM&gt;Nama Mahasiswa</b>	<b>:</b>

No	Keterangan	Pembahasan
1	Apakah anatomi itu :	
2	Posisi anatomi 	Bidang median :  Bidang Sagital :  Bidang Horizontal :  Bidang koronal :
3	:	 <p>Superior :</p> <p>Inferior :</p> <p>Anterior :</p> <p>Posterior :</p> <p>Superfisial :</p> <p>Profunda :</p> <p>Medial :</p> <p>Lateral :</p>

No	Keterangan	Pembahasan
	Proksimal : Distal :	
4	Arah pergerakan  Elevasi : Depresi : Abduksi : Adduksi : Pronasi : Supinasi : Ekstensi : Fleksi :	 <p>Sumber: <i>Kinesiologi: The Anatomy of Motion, Ellen Neall Duvall</i></p>  <p>Flexion and extension of upper limb at shoulder joint and lower limb at hip joint</p>  <p>Flexion and extension of hand at wrist joint</p>  <p>Flexion and extension of digits (fingers) at metacarpophalangeal and interphalangeal joints.</p>